# RADIOGRAPHIC EVALUATION OF FRONTAL SINUS AND ORBITAL APERTURE FOR AGE AND GENDER DETERMINATION AMONG LUCKNOW POPULATION

**DISSERTATION**

Submitted to

**BABU BANARASI DAS UNIVERSITY, LUCKNOW, UTTAR PRADESH**

In partial fulfilment of the requirement for the degree of

**MASTER OF DENTAL SURGERY**

In

**ORAL MEDICINE AND RADIOLOGY**

By


**Dr. Akansha Mishra**


Under the guidance of


**DR. DEEPAK U.**

Professor

Dept of Oral Medicine and Radiology

**BABU BANARASI DAS COLLEGE OF DENTAL SCIENCES, BBDU, LUCKNOW (U.P.)**


BATCH: 2018-2021

# DECLARATION BY THE CANDIDATE

I hereby declare that this dissertation entitled **"RADIOGRAPHIC EVALUATION OF FRONTAL SINUS AND ORBITAL APERTURE FOR AGE AND GENDER DETERMINATION AMONG LUCKNOW POPULATION"** is a bonafide and genuine research work carried out by me under the guidance of **Dr. Deepak U.**, Professor, Dept of Oral Medicine and Radiology, Babu Banarasi Das College of Dental Sciences, Babu Banarasi Das University, Lucknow, Uttar Pradesh**.**

Candidate's Signature

Date: 06/07/2021 **Dr. Akansha Mishra**

Place: Lucknow

# CERTIFICATE BY THE GUIDE / CO-GUIDE

This is to certify that the Dissertation entitled **RADIOGRAPHIC EVALUATION OF FRONTAL SINUS AND ORBITAL APERTURE FOR AGE AND GENDER DETERMINATION AMONG LUCKNOW POPULATION** is a bonafide work done by **Dr Akansha Mishra**, under our direct supervision and guidance in partial fulfilment of the requirement for the degree of Master of Dental Surgery in Oral Medicine and Radiology.


**GUIDE**

**DR. DEEPAK U.**

**Professor**

Department of Oral Medicine and Radiology

BBD College of Dental Sciences

BBDU

Lucknow (U.P.)

**CO – GUIDE**



**DR. PUJA RAI**

**Senior Lecturer**

Department of Oral Medicine and Radiology

BBD College of Dental Sciences

BBDU

Lucknow (U.P.)

# ENDORSEMENT BY THE HEAD

This is to certify that this dissertation entitled **"RADIOGRAPHIC EVALUATION OF FRONTAL SINUS AND ORBITAL APERTURE FOR AGE AND GENDER DETERMINATION AMONG LUCKNOW POPULATION"** is a bonafide work done by **Dr. Akansha Mishra**, under direct supervision and guidance of **Dr Deepak U.**, Professor, Dept of Oral Medicine and Radiology, Babu Banarasi Das College of Dental Sciences, Babu Banarasi Das University, Lucknow, Uttar Pradesh.


Seal and Signature of the HOD

**Dr. Neeta Misra**

Professor and Head

Department of Oral Medicine and Radiology

BBD College of Dental Sciences

BBDU

Lucknow (U.P)

# ENDORSEMENT BY THE HEAD OF THE INSTITUTION

This is to certify that this dissertation entitled **“RADIOGRAPHIC EVALUATION OF FRONTAL SINUS AND ORBITAL APERTURE FOR AGE AND GENDER DETERMINATION AMONG LUCKNOW POPULATION”** is a bonafide work done by **Dr. Akansha Mishra**, under direct supervision and guidance of **Dr Deepak U.**, Professor, Dept of Oral Medicine and Radiology**,** Babu Banarasi Das University, Lucknow, Uttar Pradesh.


Seal and Signature of the Head of Institution

**Dr. B Rajkumar**

Principal

BBD College of Dental Sciences

BBDU

Lucknow (U.P.)

# <u>COPY RIGHT</u>

I hereby declare that **Babu Banarasi Das University** shall have the right to preserve, use and disseminate this dissertation in print or electronic format for academic / research purpose.



Date: 06/07/2021 Candidate's Signature

Place: Lucknow **Dr. Akansha Mishra**

# ACKNOWLEDGEMENT

I take the opportunity to express my profound gratitude and deep regards to my mentor and guide, ***Dr. Deepak U., Professor, Department of Oral Medicine & Radiology, Babu Banarasi Das College of Dental Sciences (Lucknow),*** for his exemplary guidance. He has been highly motivating and thoughtful throughout the time period, in formulating this Dissertation and to bring it to a complete success. I am grateful to him for all his efforts & patience and instilling in me the joy of creative expression and knowledge.

I am deeply indebted to respected ***Dr. Puja Rai, Senior Lecturer, Department of Oral Medicine & Radiology, Babu Banarasi Das College of Dental Sciences (Lucknow),*** for her constant support and valuable advice towards my goal of completing this manuscript.

I owe my most sincere gratitude to respected ***Principal, Dr. B. Rajkumar, Babu Banarasi Das College of Dental Sciences (Lucknow),*** who provided me with the permission and facilities to complete this task.

I extend my sincere gratitude to ***Dr. Neeta Misra (Professor & Head), Dr. Priya Singh (Reader), Dr. Saurabh Srivastava (Reader) and Dr. Prathana Govil (senior lecturer)*** for all their cooperation, everlasting guidance, constant help and advice when need arose, for being there when I needed their help.

I would like to thank my colleagues ***Dr. Areeba Shahid, Dr. Ismat Fakhra*** for their valuable suggestions and constant support, and ***Dr. Himanshi, Dr. Sneha Agrawal***, and my junior ***Dr. Mona Singh, Dr. Ribhu Ganguly, Dr. Sarah Afaque, Dr. Swarna Chaturvedi*** for their help.

I would also like to thank and appreciate the efforts done by ***Mr. Praveen Kumar,*** Radiology Technician in helping me out with this study

I am forever indebted to my parents for everything I can imagine of, their bountiful affection, support, understanding and selflessness.

Above all I bow my head in gratitude to the *Almighty*, the most magnificent, ever loving, for bestowing HIS blessings & mercy on me.

- DR. AKANSHA MISHRA

# CONTENTS

# LIST OF TABLES

# LIST OF GRAPHS

# LIST OF FIGURES

# LIST OF PHOTOGRAPHS

# LIST OF ANNEXURES

# ABBREVIATIONS

- BBDCODS - Babu Banarasi Das College of Dental Sciences
- BBDU - Babu Banarasi Das University
- OMR - Oral Medicine and Radiology
- F.O. - Forensic Odontology
- FS - Frontal Sinus
- OA - Orbital Aperture
- PA Ceph - Postero- anterior cephalograms
- CT - Computed Tomography
- CBCT - Cone beam Computed Tomography

# ABSTRACT

## BACKGROUND

Forensic dentistry a branch of dentistry dealing with the proper handling and examination of evidence and proper evaluation and presentation of dental findings.

Two important parameters of this study are Orbits and Frontal sinus. The frontal sinus is as unique to each individual as a fingerprint, even in monozygotic twins. Orbital aperture is associated with morphological variations and is used in forensic as a parameter for sexual and ethnic determination in human identification. The orbital aperture is important for gender determination as orbit is resistance to damage and disintegration processes

## AIM

To determine gender and age estimation on the basis of frontal sinus and orbital aperture using digital postero-anterior cephalometric skull view.

## OBJECTIVES

. 1.To measure frontal sinus and orbital aperture for gender determination using digital postero-anterior cephalometric skull view.

2.To measure frontal sinus and orbital aperture for age estimation using postero-anterior cephalometric skull view.

3.To assess the validity of the above structures for age and gender determination

## MATERIALS AND METHODS

In the present study 200 patients (100 males and 100 females) with age range of 15- 70 years

Postero-anterior cephalograms of all the subjects involved in the study were taken with standard protocol for radiation protection.

- The maximum length and width of the right and left frontal sinus
- The maximum length and width of the right and left orbits and the inter-orbital distance

**RESULTS**

The results of present study revealed that the frontal sinus decreases with age which was statistically significant ($p<0.001$); orbital apertures showed no significant changes with increasing age ($p > 0.05$); frontal sinus and orbital aperture size was greater in male than in females which was statistically significant ($p< 001$).

**CONCLUSION**

It can be concluded that frontal sinus and orbital aperture both can be used as an asset in forensic dentistry; frontal sinus being more useful than orbital aperture which was statistically significant.

**KEYWORDS**- forensic dentistry, frontal sinus, orbital aperture, postero- anterior cephalogram

## INTRODUCTION

The word Forensic comes from the Latin word forensis: public; to the forum or public discussion; argumentative, belonging to debate or discussion.

Forensic dentistry is the branch of dentistry that deals with the legal aspects of professional dental practices and treatment and plays an important role in mass disasters (terrorist attacks, earthquakes, Tsunamis), abuse, bite mark analysis, criminal or natural deaths and injuries. Also helps in identification of decomposed and charred bodies like drowned persons, burns, and victims of motor vehicle accidents. The different methods employed in in forensic dentistry include bite mark analysis, tooth prints, Rugoscopy, Cheiloscopy, Dental DNA analysis, Radiographs [1]

Dentomaxillofacial Radiology is a valuable tool in forensic dentistry, and radiographs have been used to identify unknown human remains since the early 1900s.[2] The utilization of radiographs in identification is valuable and various morphological and pathological alterations can also be studied. Radiological identification plays an important role in forensic medicine, in the absence of comparative samples and fingerprints.[3] Metric analyses on the radiographs are of superior value due to their objectivity, accuracy, and reproducibility. Radiographic techniques determine the dimensions of the craniofacial structures.[2] Morphological features on the radiographs has two requirements to be of forensic identification value: Firstly, the feature has to be unique to the individual; secondly, has to remain stable over time regardless of the ongoing life processes. [3]

Cephalometry is a cost effective and well-established method for evaluating patients with dentofacial deformities. Posteroanterior (PA) cephalometric projections is an important adjunct for qualitative and quantitative evaluation of the dentofacial region. This radiograph is a valuable tool for comparing right and left structures as they are located at relatively equal distances from the film and radiographic source. Gross inspection of PA cephalogram provides a useful information concerning overall morphology, shape and size of the skull, the bone density as well as suture morphology and possible deviations from these.[4]

Personal identification is the establishment of the identity of an individual. The need for personal identification is seen in natural mass disasters and in man-made disasters such as terrorist attacks, bomb blasts, mass murders, and in cases when the body is highly decomposed or dismembered and in the need for social and medico-legal purposes. [5]

Two important parameters of this study are Orbits and Frontal sinus which are dimorphic, unique and can be an asset to forensic study.

The frontal sinuses are two in number and lies between the external and internal faces of the frontal bone. They are asymmetrical and lies medial part of the orbital roof. The significance of frontal sinus in forensic sex determination lies in their unique pattern.[6] The frontal sinus is as unique to each individual as a fingerprint, even in monozygotic twins.[7] The outline of the frontal sinus is irregular, and the dimensions of the frontal sinus are more convenient for being exactly measured. Both the sinuses develop at the age of two years and grow slowly until puberty, then rapidly until completing growth at around 20 years. Changes in the adult sinuses are rare and generally remain stable throughout life and hence their assessment through linear and area measurements is carried out. Studies have shown that evaluation of frontal sinus radiographs is important in determination of gender. [6]

Human skulls have been used to measure the orbital aperture and the orbital bone and the associated morphological variations which may be used in forensic medicine as a parameter for sexual and ethnic determination in human identification. The orbital aperture is important for gender determination as orbit is resistance to damage and disintegration processes.

Only few researches have been done to assess the morphology of both frontal sinus and orbital aperture, hence the need was felt to conduct a study for age and gender determination through evaluation of morphology of frontal sinus and orbital aperture.

# AIM & OBJECTIVES

**AIM**

To determine gender and age estimation on the basis of frontal sinus and orbital aperture using digital postero-anterior cephalometric skull view.

**OBJECTIVE**

1.To measure frontal sinus and orbital aperture for gender determination using digital postero-anterior cephalometric skull view.

2.To measure frontal sinus and orbital aperture for age estimation using postero-anterior cephalometric skull view.

3.To assess the validity of the above structures for age and gender determination

# REVIEW OF LITERATURE

The word Forensic comes from the Latin word forensis: public; to the forum or public discussion; argumentative, belonging to debate or discussion.

Further Keiser–Nielson (1980) defined it as "The branch of forensic medicine which in the interest of justice deals with the proper handling and examination of dental evidence and with the proper evaluation and presentation of the dental findings" [8]

Skull bones has always aided in genetic, anthropological, odontological and forensic investigation of living and non- living individual.[9]

Radiographic evaluation of various skeletal structures including skull is a potential useful procedure for identification of human remains [10]

Chronological age assessment plays important role in medico-legal practice which is complex and involve the consideration of many factors. Changes pertaining to chronological age can be seen in both hard and soft tissue; among dental hard tissues and bone are extremely resistant to fire and are usually the only remains after an extended period of burial [10]. Age estimation also provides valuable information in illegal immigrants. Skeletal, dental and psychological methods allow assessment of age to assess the degree of physical maturity of individuals.[11]

Thus, forensic odontology has gained importance as an important tool in identifying the skeletal/dental remains.

The identification of gender from human remains is of fundamental importance in forensic medicine and anthropology, especially in criminal investigations and also in the identification of missing persons ae well as in the attempts at reconstructing the lives of ancient populations. Detection of sex based on measurements and morphometry are accurate and can be used in the determination of sex from the skull [10]

Frontal sinuses are pneumatic cavities and are radiologically evident at five or six years and develop fully at the age of 20 years. Various studies have suggested that the frontal sinuses are slightly greater in males than in females. Frontal sinuses have been found different in monozygotic and dizygotic twin and is important in identification. Frontal sinus patterns have a potential aid for personal identification, age estimation and sexual dimorphism [12]

The orbit is a craniofacial structure located on the anterior surface of skull. Its morphology varies between race and ethnic groups.[13] Human skulls have been used to measure the orbital aperture &morphological variations of orbital aperture, and orbital bone is used in forensic as a parameter for sexual and ethnic determination in human identification. [2]

## HISTORICAL BACKGROUND-

The evolution of forensic odontology is dated back in the Garden of Eden. According to the Old Testament, Eve convinced Adam to make a bite mark in apple. Ancient sources contain several accounts of techniques that foreshadow the concepts of forensic science that is developed centuries later, such as the "Eureka" legend told of Archimedes.[14]

Histories of forensic odontology frequently refer to cases such as the identification of Lollia Paulina by Agrippina using visual recognition of 'distinctive teeth' Charles the bold from a missing upper tooth in 1477.

Dr. Amoedo is the father of forensic odontology. His seminal work ''L'Artdentaire en medicinelegale", was published by Masson at Paris in 1898.

M'Grath in 1869 described the use of dental characteristics to differentiate between two incinerated females, and a paper by Reid in 1884 discussed many cases using dental science for both personal identification and age assessment, one as early as 1835.[14]

During 1957, the first Central Forensic Science Laboratory (CFSL) was established at Calcutta, followed by the ones at Chandigarh and Hyderabad (1965).[15]

In India, Forensic Odontology is an upcoming branch of dentistry with a future scope of development. Dental Council of India has introduced it in the syllabus for Bachelor of Dental Surgery (BDS) but not as an individual subject in the curriculum of Dental Council of India. In the near future, Forensic odontology in India can become a separate discipline of dentistry as in the Western world.[16]

Agrippina, in 49 A.D was the first to recognized Lollia-Paulina's discoloured front teeth after her assassination.

Dentistry helps in the detection of crime or in civil proceedings. They established the essential role which forensic dentistry plays mainly in the identification of human remains.[17] Skull bones has always aided in genetic, anthropological, odontological and forensic investigation of living and non- living individual.[9]

Radiographic evaluation of skeletal structures including skull is an important for identification of human remains [10]

**Role in Medico legal aspect-**

Forensic Odontology plays a role in the law enforcement in the administration of justice. Though in developed countries this branch of dentistry is playing a useful role but as far as India is concerned its role is definitely being recognized nowadays. An overview of the basic and recent trends of this emerging branch of dentistry is presented to make the concerned professionals aware of their role in medico legal matters. [18]

The first recorded medico-legal identification was of Dr. Joseph identified using dental means in. Mass forensic identification by dentition was first used at Paris, in 1897. Forensic Odontology a combination of art and science of dental medicine. It is the proper handling, examination and evaluation of dental evidence which are then presented in the interest of justice.[19]

**FRONTAL SINUS**

The paranasal sinuses are spaces within the bones of skull, which are filled with air. These open spaces serve the purpose of warming and humidifying air, as well as giving resonance to the voice.

Paranasal sinuses are lined with ciliated columnar epithelium that produce mucus and traps inhaled pathogens and keeps the inside of nose from drying out [20]

**Development of frontal sinus –**

Frontal sinus begins to develop during the 4th foetal month after the development of frontal recess. Initially this recess is a pocket found medial to the superior aspect of uncinate process. The frontal sinus is formed by a direct extension of frontal recess into the frontal bone. Prenatally, this sinus does not expand much further. Secondary pneumatization occurs postnatally, between ages of 6 months and 2 years. [21]

The frontal sinus is not present at birth. It begins to form as two small pea sized pockets located above the orbits at two years of age and are not visible radiographically until approximately six years of age. Growth continues through puberty towards the medial portion of orbital roof and ceases at around 20 years of age, with stable shape and size.

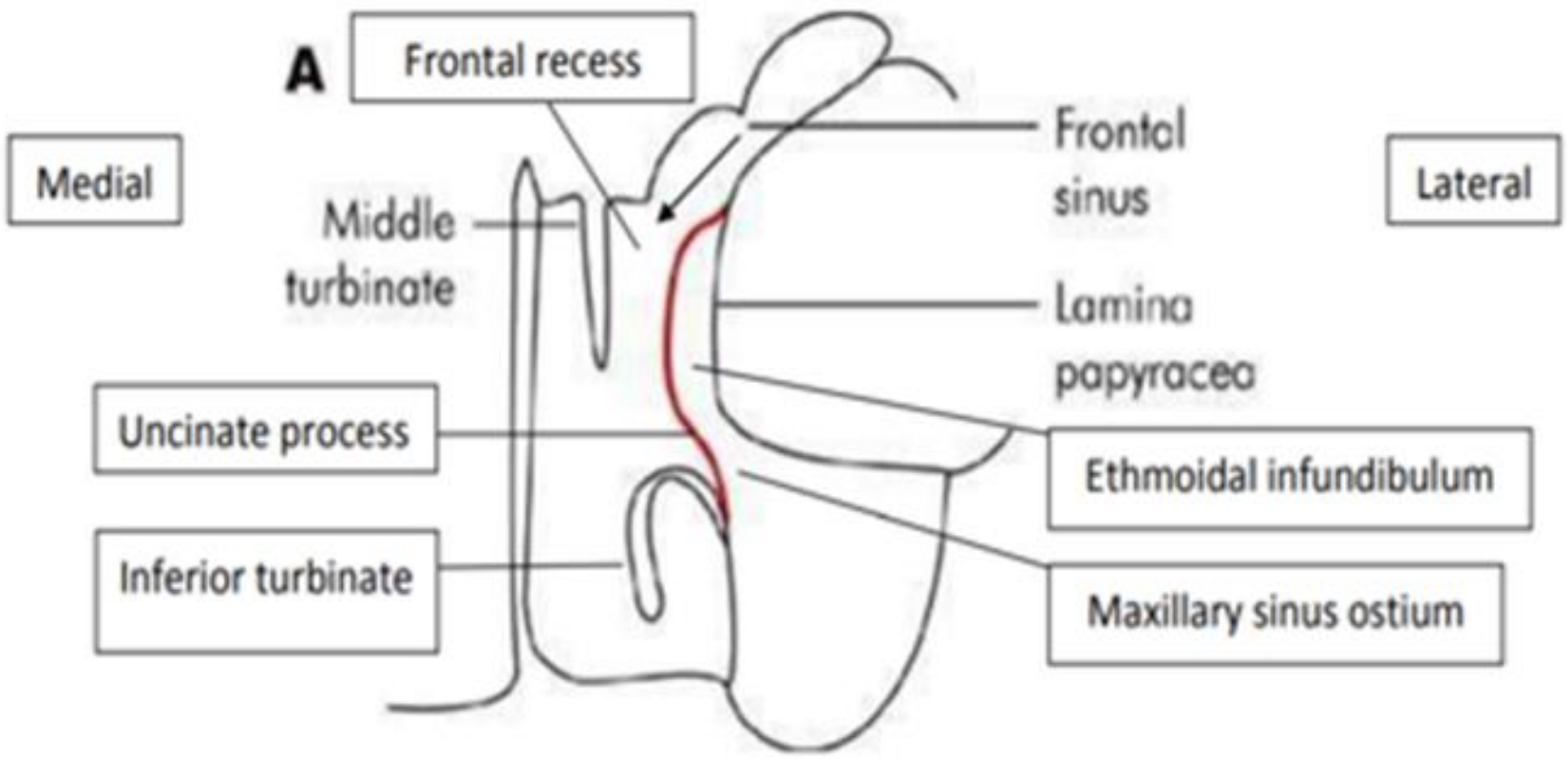


**PHOTOGRAPH 1- DEVELOPMENT OF FRONTAL SINUS**

Frontal sinus shape is unique to each individual. Studies conducted by **Tang et al 2009** examined the uniqueness of its shape & concluded that they are not alike. Studies including monozygotic twins have found that frontal sinus shape differs considerably. [22]

**<u>Anatomy of Frontal Sinus -</u>**[23].

**Situation-** Frontal sinus is a triangular, pyramid- shaped cavity extending between the ascending portion of frontal bone. Consisting of bilateral sinuses separated by a bony septum.

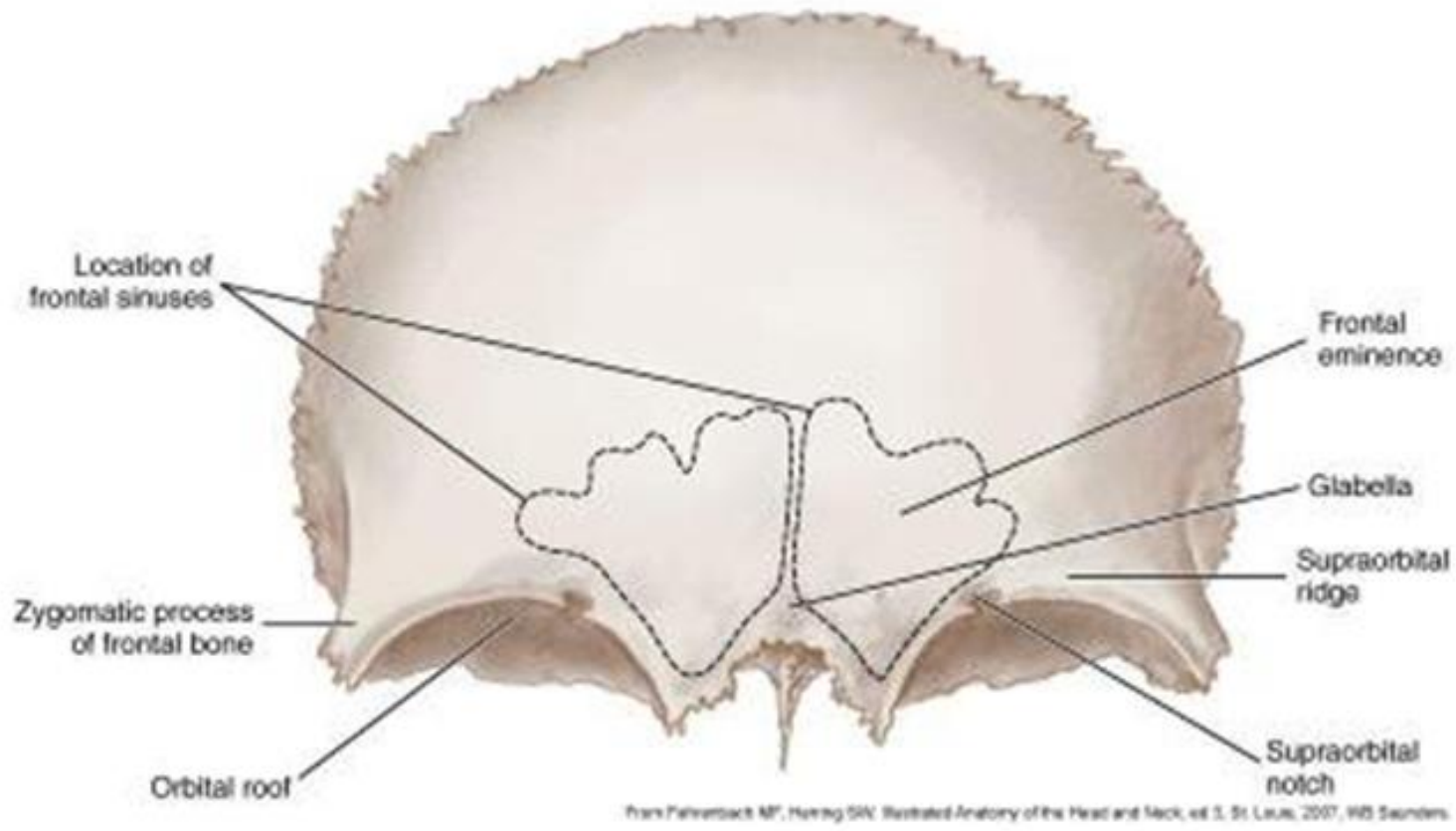


**PHOTOGRAPH 2- SITUATION OF FRONTAL BONE**

Frontal sinus shape is unique to each individual. Studies conducted by Tang et al 2009 examined the uniqueness of its shape & concluded that they are not alike. Studies including monozygotic twins have found that frontal sinus shape differs considerably. [22]

**Anatomy of Frontal Sinus -**[23].

**Situation-** Frontal sinus is a triangular, pyramid- shaped cavity extending between the ascending portion of frontal bone.  Consisting of bilateral sinuses separated by a bony septum.

**Size and Shape-** the right and left sinuses are usually unequal in shape. The volume of sinus is approximately 6-7 ml; height- 3.2cm; breadth- 2.6 cm; depth- 1.8cm.

**Arterial Supply-** supraorbital artery and anterior ethmoidal artery

**Venous Drainage-** into supraorbital and superior ophthalmic veins

**Lymphatic Drainage-** to submandibular nodes

**Nerve Supply-** Supraorbital nerve

**Relations-** infero- lateral- to the orbit; Inferiorly- to the nasal cavity; Laterally- frontal lobe of the orbit

**Opening-** into middle meatus of nose at anterior end of the hiatus semilunar.

. **<u>Frontal sinus and its use in forensic –</u>**

Uniqueness of anatomical structures and specific variations in the morphology of paranasal sinus provide the foundation stone for forensic identification of unknown deceased persons. Among the four paranasal sinuses, namely, maxillary, frontal, ethmoidal, and sphenoidal, frontal sinus is of significant forensic interest, owing to its unique presentation in each individual. Frontal sinuses are highly variable in size, ranging from few cubic centimetres to almost the whole area of the frontal lobe, with an average height of 24.3 mm and extends to approximately 29mm from the midline to the lateral wall of the sinus. The significance of frontal sinus in personal identification is emphasized by anatomists, radiologists, as well as anthropologists who have stated that no two frontal sinuses are alike. Studies have been done to utilize sinus radiography for the identification of remains as well as determination of sex and race. [24]

The application of radiology in forensics was firstly introduced in 1896, following the discovery of X-rays by Roentgen. Schuller was the firstly reported the use of radiographs for the purpose of identification in 1921. Juan Rogelio et al. stated that the identification by comparing frontal sinus radiographs was first suggested by Schuller in 1943. In 1925, Culbert and Law performed the first case of identification using the frontal sinus, published in 1927.[25]

Frontal sinus morphometric classifications used for forensic application given by **Yoshino et al., &Taniguchi et al**., is based on frontal sinus pattern such as symmetry of sides, aplasia, right or left dominance which is in combination with number of lobulations.

Yoshino's frontal sinus pattern is as follows 1. Frontal sinus size 2. Bilateral asymmetry 3. Superiority of size 4. Outline of upper border 5. Partial septa 6. Supraorbital cells.

**Taniguchi et al.,** established frontal sinus pattern based on symmetry aplasia, right or left dominant asymmetry in combination with number of lobulation. [7]

The uniqueness of the anatomy of the sinus acts as a helpful aid in forensic dentistry. These sinuses are considered similar to fingerprints, concerning the fact that each frontal sinus is distinctive and unique. Various studies reported successful use of frontal sinuses in personal identification; **Cameriere et al., Kirk et al., Christensen et al**., reported 100 % accuracy. **Kirk et al**., reported that age, gender and cause of death did not affect the ability to obtain a match between anti mortem and post mortem reports.

Various factors leading frontal sinus a reliable indicator for personal identification:

- It is a highly variable anatomical structure, even the frontal sinuses of monozygotic twins show considerable difference
- It is considered to be relatively stable during the adult life until old age, while pneumatisation might occur owing to atrophic changes [24]
- The anatomic location of the sinus ensures that the region remains intact even when subjected to abuse or trauma. The thick bone of the anterior wall of the sinus and its curved convexity forms a barrier to resist fracture thus providing great resiliency. It has been found that a force of 800–1600-foot pounds is required to fracture the anterior wall. That is twice as much required to fracture the para symphyseal area of the mandible and 50% more than that required to fracture the malar eminence of zygoma. It has become common practice to take paranasal sinus radiographs for diagnostic purposes and hence can be easily available for comparative radiography. [25]

**Belaldavar et al. 2014 [26]** conducted a study on 300 patients which included 147 males and 142 females undergoing postero anterior views. The mean values of the height, width and area are greater in males and the right frontal sinus is larger than the left sinus in both the genders. The analysis gives an average concordance index for sex determination of 64.6%. The study concluded that the frontal sinus shows an accuracy in determining sex, but high precision in human identification.

**Gopal KS, et al., 2016 [27]** used CBCT images to establish pattern of frontal sinus and nasal septum and reported its possible application for personal identification. Frontal sinus symmetry was observed in 43.7 % individuals and asymmetry in 48.75 %. Bilateral aplasia in 5% and unilateral aplasia was seen in 2.5 %. Straight nasal septum was seen in 33.75%, right deviation in 30%, and left deviation in 22.5% individuals.

.

## AGE RELATED CHANGES IN FRONTAL SINUS RADIOGRAPHICALLY-

The frontal sinus is absent at birth. The sinuses begins forming at two years of age; but are they are not visible radiographically until approximately six years of age (da Silva et al., 2009; Verma et al., 2015). Growth continues through puberty and ceases at about 20 years of age, with stable shape and size. [28]

Frontal sinus development and growth is associated with specific age related stages of skull growth. Radiographic development of frontal sinus

PHOTOGRAPH 3- Radiograph depicting an individual with frontal sinuses that are absent (birth to 5 years).

Individuals in the first stage of frontal sinus development shows also two small, kidney bean shaped areas of radiolucency on the medial portion of the superior border of the orbits near the anatomical landmark glabella.

PHOTOGRAPH 4-Radiograph of an individual during the initial stage of frontal sinus development (age 6–7).

Individuals between the ages of eight and ten years old were in the initial stage of frontal sinus expansion. In these individuals, the two areas of radiolucency had expanded medially and laterally, but were still in the glabella region of the frontal bone

PHOTOGRAPH 5-Radiograph depicting an individual during the initial stage of frontal sinus expansion (age 8–10)

Individuals between the ages of eight and ten years old were in the initial stage of frontal sinus expansion. In these individuals, the two areas of radiolucency had expanded medially and laterally, but were still in the glabella region of the frontal bone

PHOTOGRAPH 6-Radiograph of an individual with a fully formed frontal sinus (age 11–18).

The final stage of development includes individuals from 11 to 18 years of age. The sinus is larger and more cavernous and expanded laterally and superiorly on the frontal bone [22]

**ORBITAL APERTURE**

In forensic anthropology, the personal identification of human skeletal is crucial in mass disasters and accidents. The skull is second most unique, versatile, and dimorphic anatomical structure with 92%. Various anatomic structures as orbital aperture, Sella turcica, frontal sinus, nasal septum can be used as adjuvant tool for personal identification. The variation in orbit and the orbital aperture plays an important role in identifying the dead or decomposed human remains. .[29]

**DEVELOPMENT OF ORBIT-**

The bones of the orbit develop through both endochondral and intramembranous ossification. The sphenoid and ethmoid bones form mostly via endochondral ossification while the frontal bone is formed by intramembranous ossification.[30] Development of orbit takes place in a chronological fashion separating the prenatal period into an embryonic period, expanding from the first 8 weeks postfertilization, and the fetal period, which extends the rest from postfertilization week 9 until birth. Intense organogenetic activity characterizes the embryonic period, whereas the fetal period is hallmarked by less intense changes.[31]

**Tomasik et al., 2005** conducted a study to describe the development of human and eyeball and orbit during fetal life. The study included 36 fetuses (18 eyes and 18 orbits) with gestational age ranging from 17 to 28 weeks. The axial length and equilateral diameters of the eyeball as well the depth and well the depth and width of the orbits increases with age. It was uncertain that the growth of the eye during fetal life is correlated with growth of the orbit. [32]

**ANATOMY –**

The orbit forms a bony pyramid with four walls: roof, lateral wall, floor, and medial wall. The base of the pyramid forms the orbital entrance, which is rectangular.[33] Seven bones forming the orbit are frontal, ethmoid, lacrimal, sphenoid, zygomatic, palatine, and maxilla. These bones are arranged in pairs, with the three walls with the exception of the medial wall.[34]

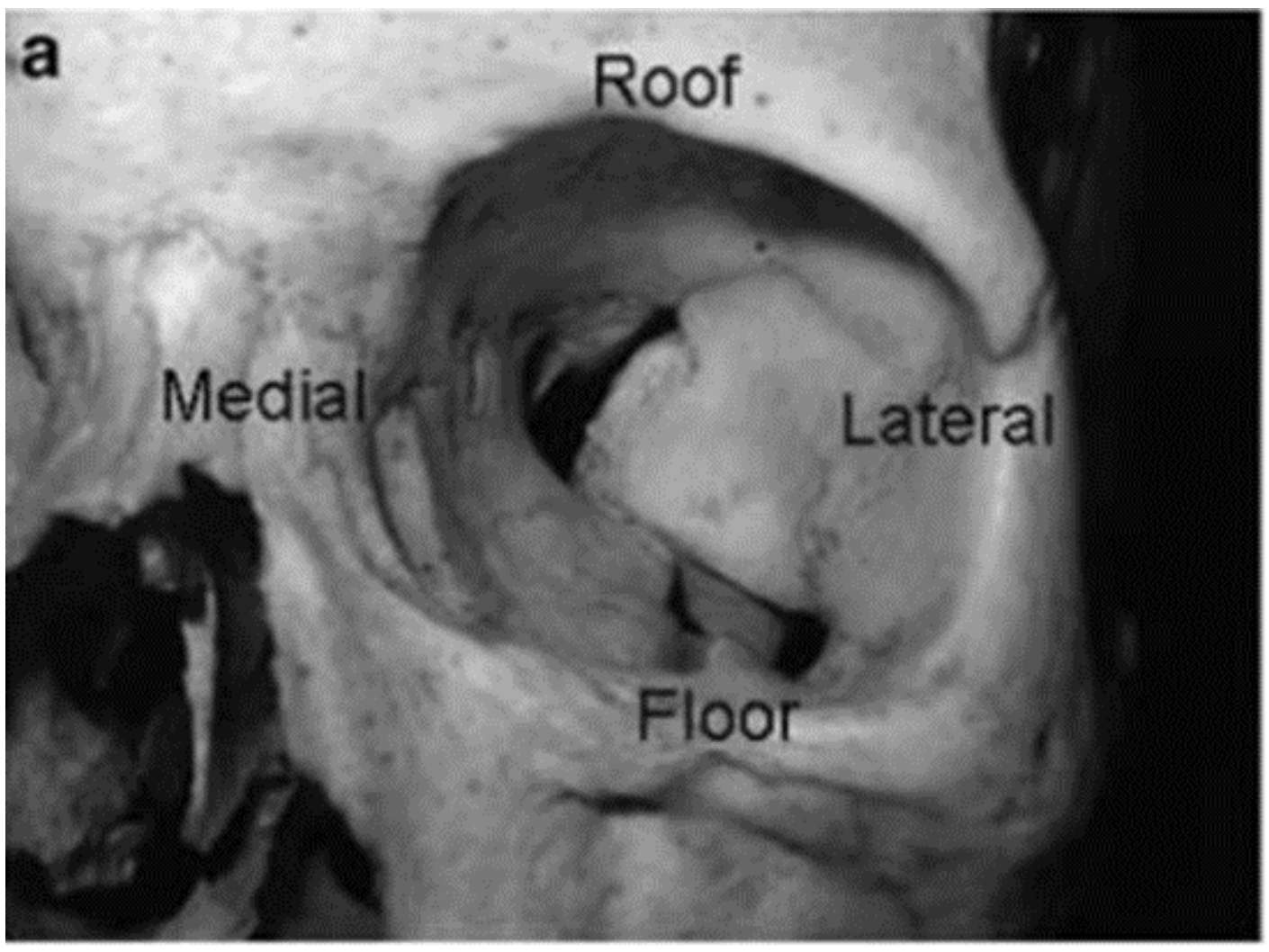


**PHOTOGRAPH 7- Walls of the Orbit**

The orbit measures 4 cm wide and 3.5 cm high and is rotated laterally. The orbits expand to a maximum dimension 1 cm behind the rim. The **apex** of the orbital pyramid is situated 44–50 mm posteriorly and contains neurovascular structures. The **medial walls** are parallel. Each **lateral wall** is rotated at 451 angle. The orbital volume is roughly 30 ml. There is some variation with sex and race. [31]

**Atrial Supply-** The ophthalmic artery serves as the main arterial supply of the orbit along with the maxillary and middle meningeal arteries, which are branches of the external carotid artery.

**Venous Drainage-** **1. Superior ophthalmic vein:** accompanies the ophthalmic artery. Lies above the optic nerve and communicates anteriorly with the supraorbital and angular veins.

**2. inferior ophthalmic vein:** runs below the optic nerve and communicates with pterygoid plexus of veins.

**Lymphatics-** drain into the preauricular parotid lymph nodes. [23]

**Nerves of the Orbit-** The optic nerve (CN II) is the main nerve and it travels from the retina, which is the inside of the orbit, through the optic foramen.

The ophthalmic nerve (first division of the trigeminal nerve (CN V) which is responsible for conveying sensory information from the orbit, upper eyelid, lacrimal gland, conjunctiva, nasal mucosa, frontal sinus, external nose, and scalp. The ophthalmic nerve passes through the superior orbital fissure and divides into specialized nerves.

**Muscles**

Seven extraocular muscles are associated with the orbit. All but the inferior oblique

muscle originates at the orbital apex. All of the rectus muscle originates at the annulus of Zinn. The superior oblique originates medial to optic foramen. All of the extraocular muscles insert on the globe except the levator palpebrae superioris (responsible primarily for eyelid elevation). [30]

**Orbital aperture and its use in forensic-**

The orbital aperture is the entrance to the orbit in which most important visual structures such as the eyeball and the optic nerve are found. It is used for evaluation and recognition of the face. The orbital aperture is the opening of the orbit as well as plays an important role in the evaluation and recognition of the face. The dimensions of the orbital aperture may be useful for the reconstruction of the orbit in the treatment of the aforementioned conditions in different ethnical groups [35]

Orbital aperture is determined by the shape of the face and varies with race, regions within the same race and periods in evolution. Different studies have shown some level of racial and ethnic variation in orbital aperture of various population groups.

Facial aging involves the aging of soft tissue and bony structures. The aging process affects the facial bones. In regards to aging of the bony orbit, male skulls are found to show enlargement in the bony orbit with changes with increasing age. The volume of the orbit was shown to increase with age

**Kahn et al., 2008** conducted a study on 60 subjects (30 males, 30 females) to demonstrate changes in the bony aspect of orbit in both male and female subjects using computed tomography (CT) scans. The study resulted that the orbital aperture width and area in both subjects of the orbit changes with age leading to the appearance of eye and orbit.[36]

**Rossi et al., 2012** evaluated the dimensions of orbital aperture in 97 Brazilian subjects by posteroanterior radiographs techniques to verify its relationship with gender and concluded that the gender difference was highly significant and that orbital aperture width, area, and inter-orbital distance were larger in males than in females.[37]

**AGE RELATED CHANGES IN ORBITAL APERTURE RADIOGRAPHICALLY-**

The aging process affects the facial bones. Studies have shown that the bony mid face undergoes a process of bony resorption and volume loss with increasing age.

The orbital aperture increases with age. Resorption is, however, uneven and site specific. The superomedial and inferolateral aspects of the orbital rim recedes the most. . In contrast, the central part of the superior and inferior orbital rims is more stable, with little if any resorption occurring with age. [38]

**Pessa et al**., found no significant changes in the orbital angle (superior-to-inferior midorbital rim points on the lateral view) with aging, indicating orbital rims do not recede with increasing age.

**Mendelson et al**. **2007** conducted a study on Facial CT scans for 62 patients in Australian population ranging in age from 21 to 70 years. Length of the orbital roof and floor (at the midaxis of each orbit) were measured and found no significant changes in these distances with aging, indicating that the central portion of the superior and inferior orbital rims do not recede with aging.[39]

**Weaver et al., 2015** [40] conducted a study on 39 head CT images three dimensionally and to measure ocular and orbital parameters to measure eye and orbit. The study resulted that the orbit widened with age, and varied significantly between the genders.

## POSTERO-ANTERIOR CEPHALOGRAMS

Radiographs play an important part in forensic odontology, mainly to establish identification. A precise form of comparison between antemortem and postmortem radiograph can be made. Comparable radiographs are an essential for forensic dentistry.[41]

Metric analysis on the radiographs of value due to presence of objectivity, accuracy and reproducibility. Radiographic techniques are used to determine the dimensions of different structures.[42] Plain radiographs are routinely used for diagnosis in dentistry. They help in assessment of anatomical structures and their variations, and the detection of abnormalities in the region assessed.[43]

Since the introduction of conventional PA Cephalograms in the 1930s, it has been used for the study facial asymmetry. The PA cephalograms provides valuable information which is not only useful for facial asymmetry but also for evaluation of craniofacial skeleton and dentoalveolar structures. Thus, PA cephalometric projections constitute an important adjunct for qualitative and quantitative evaluation of dentofacial region. PA Cephalogram can be used to compare right and left structures since they are located at relatively equal distances from film and x ray source. Due to which, the effects of unequal enlargement by diverging rays are minimised and distortion is reduced. This allows for valid comparison between two sides of the skull to evaluate asymmetry.[44]

Main indications of posteroanterior view :- [45]

• Fractures of the skull vault

• Investigation of the frontal sinuses

• Conditions affecting the cranium, particularly:

— Paget's disease

— multiple myeloma

— hyperparathyroidism

• Intracranial calcification.

**Image Receptor and Patient Placement-[46]**

The image receptor is placed in front of the patient which is perpendicular to the midsagittal plane and parallel to the coronal plane. The patient is positioned such as canthomeatal line forms a 10-degree angle with the horizontal plane and Frankfort plane forms a 90-degree angle to the image receptor. In the posteroanterior (PA) skull projection, the canthomeatal line forms a 90 degree to the image receptor.

**Position of the Central X-Ray Beam** –

Central beam forms a 90-degree angle to the image receptor which is directed from the posterior to the anterior and is centered at the level of the bridge of the nose.

**Resultant Image-**

The midsagittal plane divides the skull image into two symmetric halves. The superior border of the petrous ridge should lie in the lower third of the orbit.

| | |
|---|---|
| Patient placement | Canthomeatal line at 10 degree with the film |
| Central Beam | Beam perpendicular with film |
| Diagram of Patient Placement | 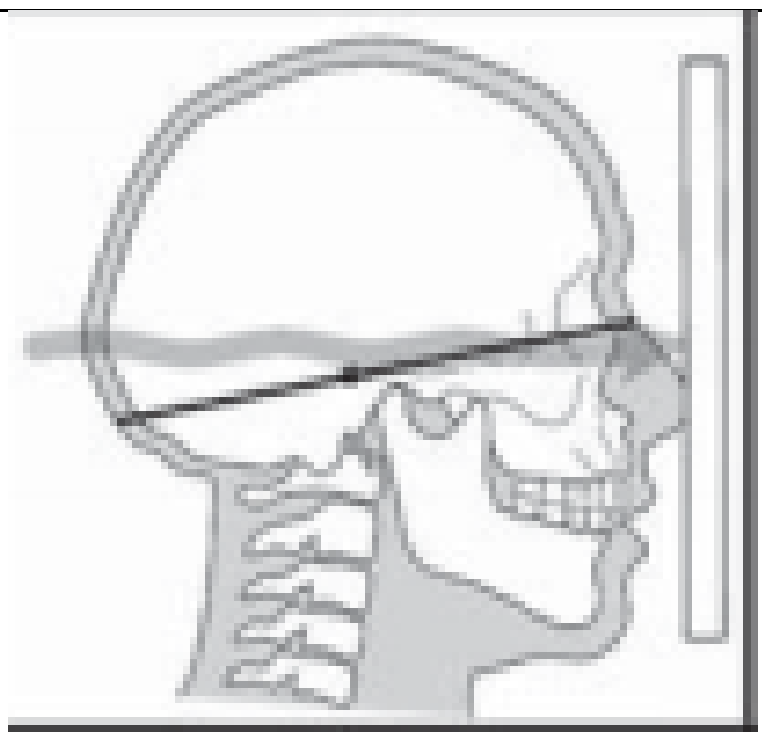 |

| | |
|---|---|
| Illustration of Patient Placement |  |
| Skull View |  |
| Resultant Image |  |

**PHOTOGRAPH 8- PATIENT POSITIONING AND RESULTANT IMAGE**

Different studies conducted on human dry skulls in order to identify the potential projection errors of lateral, postero-anterior (PA) and submentovertex (SMV) cephalometric radiographs due to head rotation in the vertical z-axis from 0 to ±14 degrees at 2degree intervals. The study concluded that SMV radiographs are less vulnerable to head rotation. [47]

Studies conducted to assess the accuracy of transverse measurements on CBCT and conventional posteroanterior (PA) cephalograms. The study concluded that CBCT was more accurate than the conventional PA cephalogram and. Changes in head position may affect the transverse measurements and thus the treatment plan.[48]

**DIGITAL IMAGING TECHNOLOGY**:

There are different generations of software that can be used for tracing both through the use of digitizers and directly on screen- displayed digital images. First-generation computer-based analysis systems used digitizer pads for tracing conventional cephalometric films; second-generation systems use scanners or digital cameras to export cephalometric images to measurement programs & third-generation systems transmits digital radiographs directly to a computer database through the use of photostimulable phosphor plates, charge-coupled device receptors, or direct digital systems. There are several advantages, as image acquisition, reduction of radiation dose, image enhancement, elimination of technique-sensitive developing processes, and image sharing.[48]

**TRACING TECHNIQUE**:

Traditionally, cephalometric analysis has been performed manually by tracing radiographic landmarks on acetate overlays and measuring linear and angular variables. Despite its widespread use, the technique is time-consuming and has several drawbacks, including a high risk of error during hand tracing, landmark identification, and measurement.[49]

The use of computers reduces the errors and provide standardized, fast, and effective evaluation along with high rate of reproducibility. [50]

The posteroanterior (PA) cephalogram is useful in evaluating the craniofacial structure in both transverse and vertical dimension. In computerized cephalometric analysis, accurate distances of structures can be measured. [49]

**Comparision between digital and tracing technique**

**Paixão et al.,2010** conducted a study on 50 lateral cephalometric radiographs to compare angular and linear cephalometric measurements obtained through manual and digital cephalometric tracings using Dolphin Imaging® 11.0 software. The study concluded that conventional and computerized methods showed consistency in all angular and linear measurements. The computer program Dolphin Imaging® 11.0 can be used reliably as an aid in diagnosing, planning, monitoring and evaluating orthodontic treatment both in clinical and research settings.[50]

**Mahto RK et al., 2016** conducted a study on 50 pretreatment lateral cephalgrams to show comparison of cephalometric measurements obtained from two computerized cephalmetric software's i.e., Dolphin and AutoCEPH with manual tracing. Intraclass correlation coefficient (ICC) was used to determine measurements and agreements between linear and angular measurements obtained from all parameters while comparing three methods, i.e., manual tracing versus AutoCEPH, manual tracing versus Dolphin and AutoCEPH versus Dolphin. The study concluded that a high level of agreement for cephalometric measurements was obtained from both the computerized software Dolphin and AutoCEPH in comparison with manual tracing.[51]

**Pradip et al., 2018** conducted a study on 60 pre-treatment (PA) cephalograms to evaluate the reliability and accuracy of linear and angular cephalometric measurements obtained from two computerized cephalometric analysis software programs, namely AutoCEPH© and Dolphin® as compared to manual tracings in posteroanterior (PA) cephalometry. Intraclass correlation coefficient (ICC) was used to determine measurements and agreement between linear and angular measurements obtained from the three methods. The study concluded a high level of agreement (ICC >0.8) for cephalometric measurements was obtained from both the computerized softwares Dolphin® and AutoCEPH© in comparison with manual tracings·[49]

## CLINICAL STUDIES –

**Kahn M. D. et al (2008)** [44] conducted a study to demonstrate changes in bony aspects of the orbit with age and changes in facial cosmetic. Computed tomography (CT) scans were conducted on 60 subjects (30 male and 30 female); age range from 25 to > 65 years. Orbital aperture width and area was measured on 3-D model. Orbital aperture width and area showed increase with increasing age in both genders. The superior orbital rim receded medially with age and inferior orbital rim recedes laterally in female population, while male subjects had a recession of the entire inferior orbital rim.

**Rubira-Bullen IR et al (2010)** [42] conducted a study on 145 in Brazilian population posteroanterior facial radiographs (Caldwell projection) to determine the width and height distances of the frontal sinus. In the study 116 (80%) were males and 29 (20%) females. The age distribution was as follows: 17 subjects from 14 to 20 years; 35 subjects from 21 to 30 years; 49 subjects from 31 to 40 years; 22 subjects from 41 to 50 years; and 17 subjects 51 years and older. The height and width of the frontal sinus were measured using rules and a viewer box. The relationship between frontal sinus size and side of the face, and size and age were evaluated. The study concluded that 31 (21.4%) cases had a larger right side; 57 (39.3%) had a larger left side and 57 (39.3%) showed almost the same size for both cavities. There was a significant correlation between width and height of frontal sinus but there was no significant difference among the age groups studied (Kruskal-Wallis, p > 0,05) regarding the height and width of the frontal sinus.

**Tiwari P. et al (2016)** [52] conducted a study at Department of Oral Medicine and Radiology, Rishiraj College of Dental Science and Research Centre, Bhopal to assess the role of frontal sinus in personal identification by co-relating with gender and age. Postero-anterior cephalograms of the subjects were taken. 160 individuals i.e. 80 males and 80 females, individuals were in age group of 15-55 years. The study concluded that total frontal sinus height, width and area were compared which showed greater in males than female. There was a significant difference between different age groups for left frontal sinus height.

**Soman A. B. et al (2016)** [7] conducted a study on 200 subjects (100 males and 100 females) Davangere, Karnataka to analyse morphology of frontal sinus in relation to age and gender using posteroanterior (PA) cephalogram radiographs age ranging from 14- 45 years. The right and left length was greater in males and females and left width increases with age in females and males. The average frontal sinus area was found to be larger in males than females. The mean values for length, width, and area of the frontal sinus were greater in males than females.

**Ghorai L.et al (2017)** [2] conducted a retrospective study to evaluate the orbital aperture dimensions in Indian individuals and verify their relationship with gender. Digital posteroanterior radiographs of 50 males and 51 females were taken, in the age group between 20 and 50 years. The width and height of the orbits and the inter-orbital distance were measured. The orbital width (left and right) and inter-orbital distance were greater in males compared with females and were statistically significant.

**Botwe O. B. et al (2017)** [13] conducted a retrospective cross-sectional study to determine the orbital index of adult Ghanaians using 350 adult Ghanaian head computed tomography images. The study consisted of 167 (47.71%) female and 183 (52.29%) male. The age range was 18–93 years. The orbital width (OW) and orbital height (OH) were recorded. The range of OH was more in males than in females. The general range of OW was similar in both the genders.

**Gadekar et al., 2019** [54] conducted a study on 400 individuals in Indian population at Maratha Mandal's NGH Institute of Dental Sciences and Research Centre, Belgaum, Karnataka, India with ages 21–30 years were included. The digitized posteroanterior skull radiographs were obtained. The study showed the presence of bilateral frontal sinus in 87.7% and bilateral absence in 8.0% of the individuals and the absence of left and right frontal sinus in 3.3% and 1%, respectively. The present study concluded that the frontal sinus is asymmetrical and unique and can be used in personal identification.

**Kanjani et al (2019)** [55] conducted a study to determine the orbital aperture dimensions on posteroanterior (PA) cephalograms in North Indian population for personal and gender identification on 250 males and 250 females. In this study height and width of the orbits with the interorbital distance were measured and resulted that the orbital height, orbital width, and interorbital distance were significantly greater in males than females.

**Mahalakshmi M et al., (2019) [56]** conducted a study on 100 retrospective postero-anterior radiographs were selected in the age range of 18 to 50 years. The width and height of orbit and inter-orbital distance of the orbits were measured. Mean orbital width in males was 4.91 and females was 4.97. The observed mean difference was statistically significant (P-0.005). Mean orbital height in males was 4.96 and females was 4.86. The observed mean difference was statistically significant (P-0.001) The mean inter-orbital distance in males was 3.37 and females was 3.00.

# MATERIAL AND METHODS

This study was conducted in Department of Oral Medicine and Radiology of Babu Banarasi Das College of Dental Sciences, Lucknow (U.P.). Ethical clearance for the study was obtained from the institutional ethical committee. (IEC code- 11) (BBDCODS/01/2019) in accordance with the declaration of Helsinki for research involving human subjects

The study population was drawn from the patients attending the outpatient Department of Oral Medicine & Radiology. For the study purpose 200 subjects were examined randomly, aged between 15-70 years, and divided into 2 groups. Group A consist of 100 males and Group B consist of 100 females. Two hundred postero-anterior cephalometric radiographs of the subjects were studied and send for statistical analysis.

**ARMAMENTARIUM for examination of patients**

1. Dental chair with illuminating facility
2. A pair of sterile disposable gloves and mouth masks
3. Stainless steel kidney tray, mouth mirror, straight probe, tweezers and explorer

**Inclusion criteria**

1. Subjects who are well oriented to time, place and person
2. Subjects of either sex aged between 15 – 70 yrs.
3. Subjects with no visible features of asymmetrical skull

**Exclusion Criteria**

1. Subjects who are uncooperative, unstable or unable to undergo cephalography procedure and subjects who are not willing to give their consent
2. Subjects with any history of trauma or surgery of skull
3. Subjects with any ailment of paranasal sinuses
4. Subjects with any other systemic or congenital disorder
5. Radiographs with artifacts, improper orientation and poor quality

**SAMPLING METHOD**

1. The study group consisted of 200 individuals within the age group of 15-70 years having 100 male and 100 female patients were included through random sampling method

2. The subjects were selected according to the inclusion and exclusion criterion

3. A detailed case history was recorded in a case history proforma

4. Following the examination of patient, each patient was informed about the procedures and was given appropriate instructions after a written consent was taken from patients.

**MATERIALS AND EQUIPMENTS** Used in the study with specifications and Company

**Materials**

- Digital panoramic machine [Planmeca Proline XC, SN: XC430638, 180-240V, 50 Hz] with AERB (Atomic Energy Radiation Board) certified quality assurance facility

- Planmeca Romexis 2.9.2.R software with computer

**Methodology:**

In the present study, all the subjects fulfilling the above criterion were enrolled after obtaining informed consent.

All the enrolled patients within age group of 15 – 70 years with equal gender distribution were included

- Postero-anterior cephalograms of all the subjects involved in the study were taken and all the standard protocol for radiation protection were followed

- The image receptor is placed in front of the patient which is perpendicular to the midsagittal plane and parallel to the coronal plane.
- The patient is positioned such as canthomeatal line forms a 10-degree angle with the horizontal plane and Frankfort plane forms a 90-degree angle to the image receptor.
- In the posteroanterior (PA) skull projection, the canthomeatal line forms a 90 degree to the image receptor. the image receptor is positioned in front of the subjects included perpendicular to the mid sagittal plane and parallel to the coronal plane.
- Central beam forms a 90-degree angle to the image receptor which is directed from the posterior to the anterior and is centered at the level of the bridge of the nose.
- The midsagittal plane divides the skull image into two symmetric halves. The superior border of the petrous ridge should lie in the lower third of the orbit.

- All the postero-anterior cephalograms were taken with the following exposure parameters 68 kVp,5 mA and 17 sec

**Procedure for measuring frontal sinus and orbital aperture**

- The maximum length and width of the right and left frontal sinus were measured and the right and left areas were obtained
- The maximum length and width of the right and left orbits and the inter-orbital distance were measured
- All the relevant data were entered in the proforma. It was then sorted, tabulated and statistically analysed to draw conclusion


**PHOTOGRAPH 9- Armamentarium**


**PHOTOGRAPH 10**- Patient along with the postero- anterior cephalometric machi

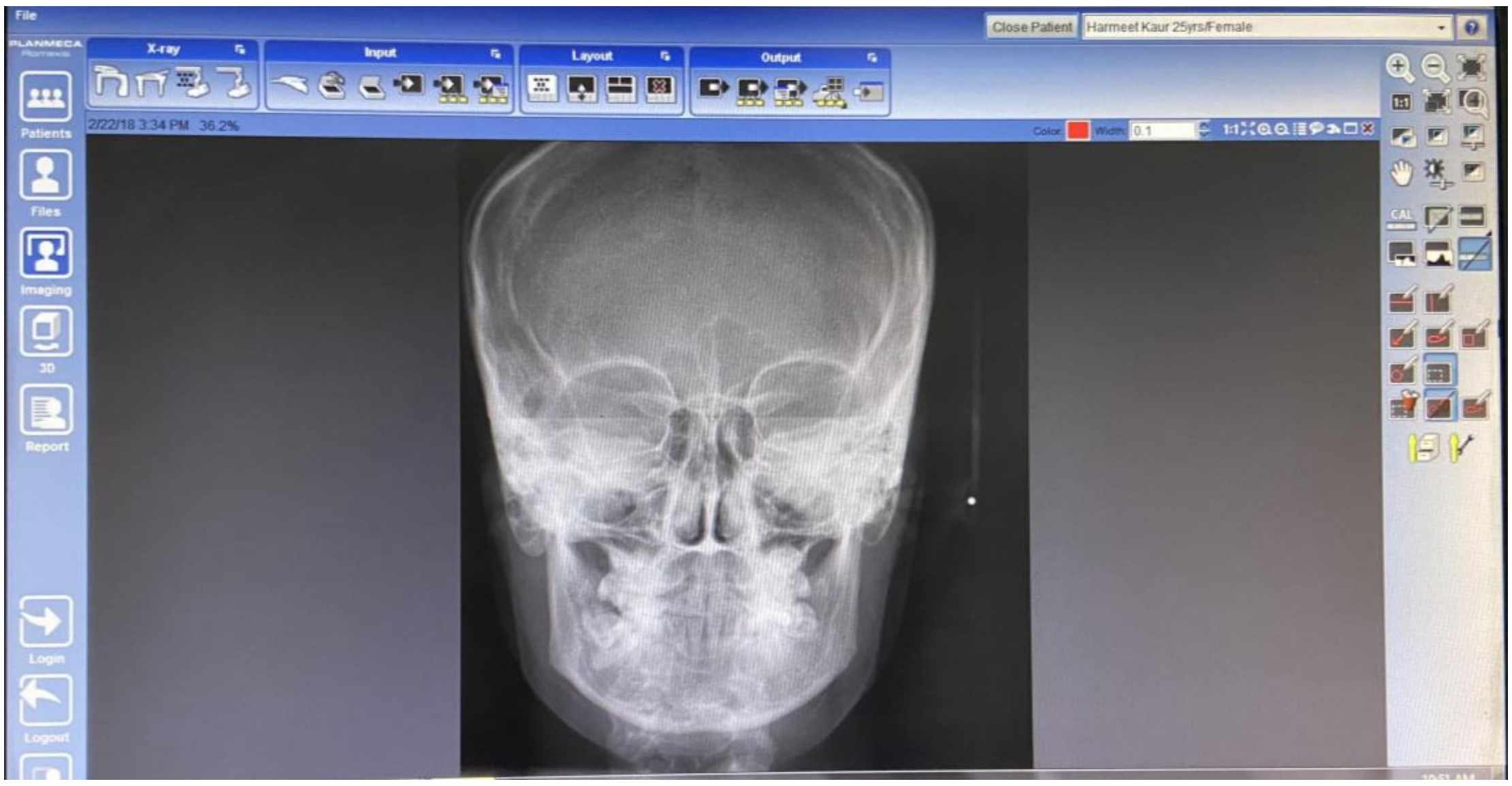


**PHOTOGRAPH 11:** Romex Software used for taking Postero-anterior Cephlaometric Radiograph

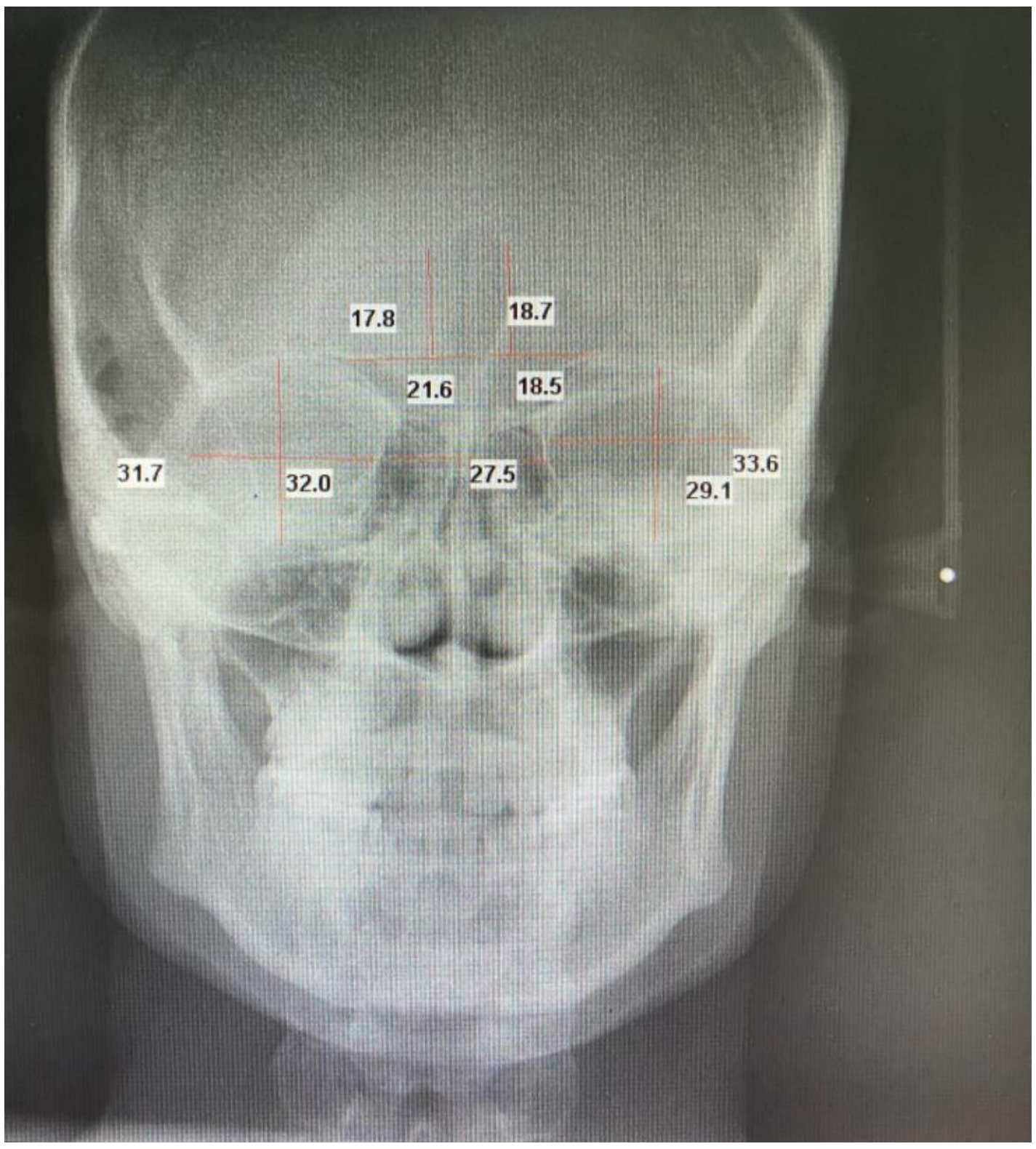


**PHOTOGRAPH 12**: Postero-anterior Cephalogram with the measurements of both right and left frontal sinus (length and width); both right and left orbital aperture (length and width); interorbital distance

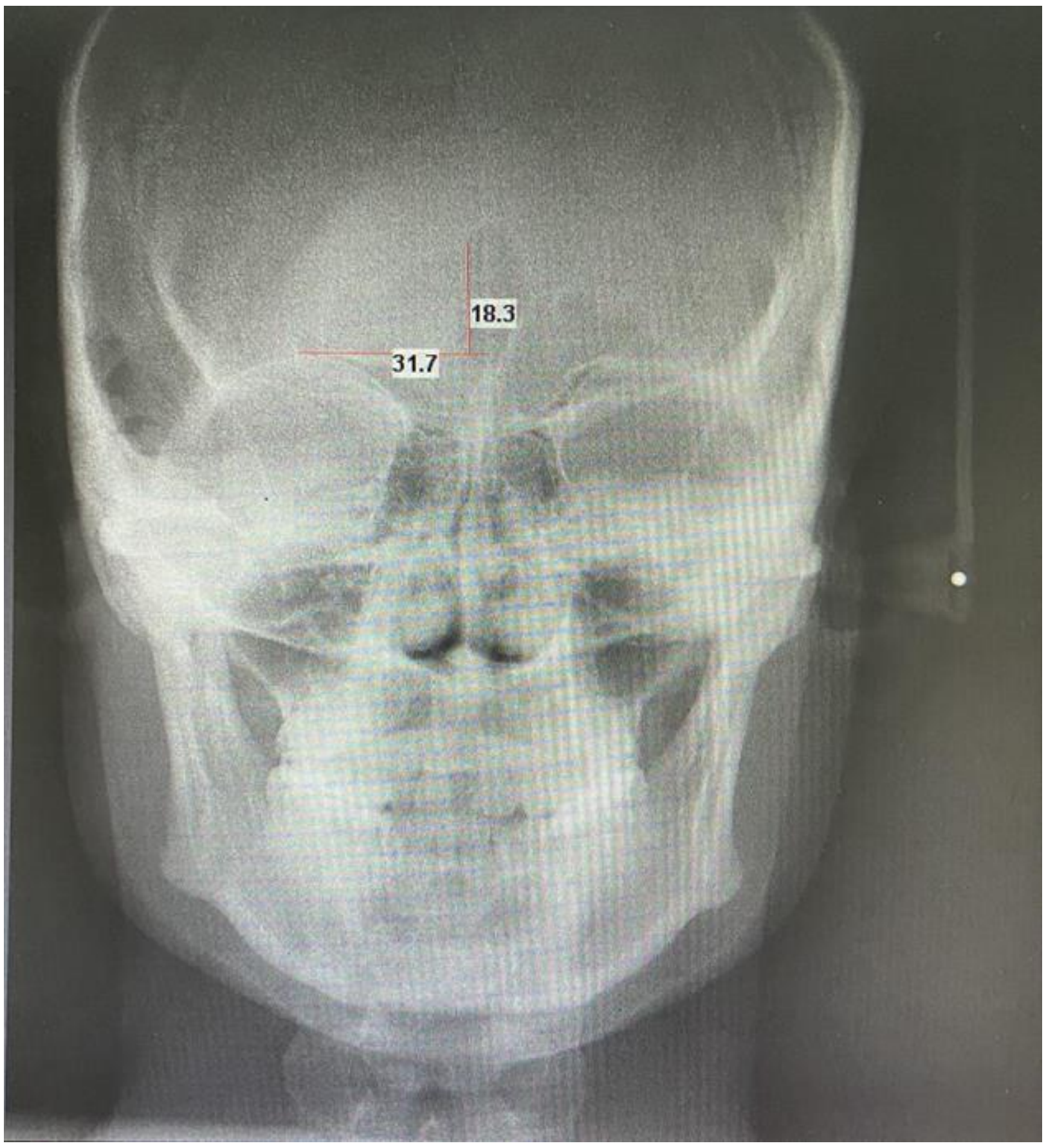


**PHOTOGRAPH 13**: measurement of frontal sinus (length and width)

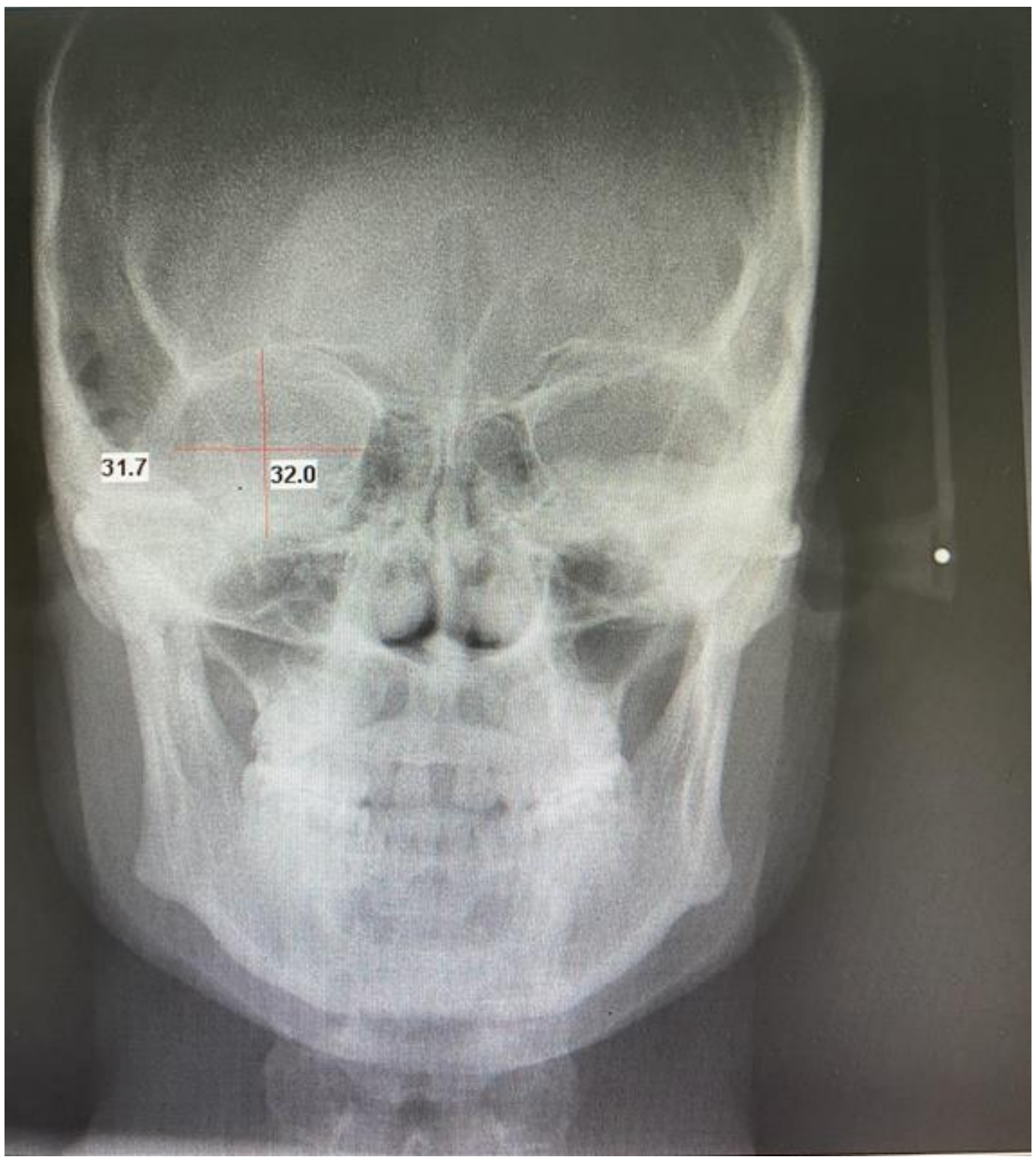


**PHOTOGRAPH 14:** measurement of orbital aperture (length and width)

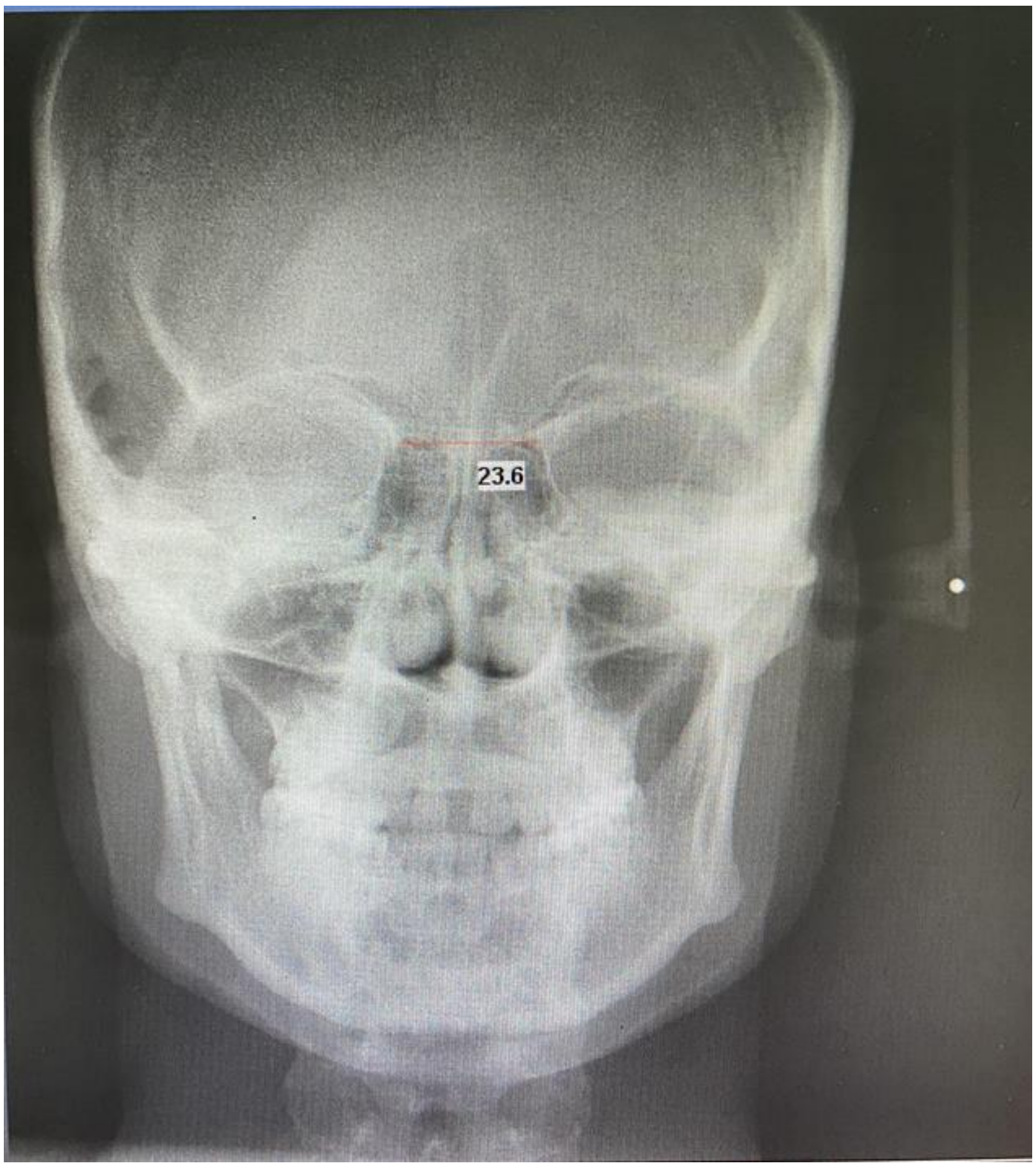


**PHOTOGRAPH 15**: measurement of interorbital distance

# OSERVATIONS AND RESULTS

The present study was conducted in the Department of Oral Medicine and Radiology of Babu Banarasi Das College of Dental Sciences, Lucknow (UP) with the aim to determine gender and age estimation on the basis of frontal sinus and orbital aperture using digital postero-anterio cephalometric skull view.

A total of 200 subjects were included in the study with 100 males and 100 females with age range 15-70 and above years.

**Table 1: Age and Gender distribution of the subjects**

| Age and Gender | No. of subjects (n=200) (%) |
|---|---|
| Age (yrs): | |
| 15-25 | 41 (20.5) |
| 26-35 | 40 (20.0) |
| 36-45 | 43 (21.5) |
| 46-55 | 50 (25.0) |
| >55 | 26 (13.0) |
| Gender: | |
| Female | 100 (50.0) |
| Male | 100 (50.0) |

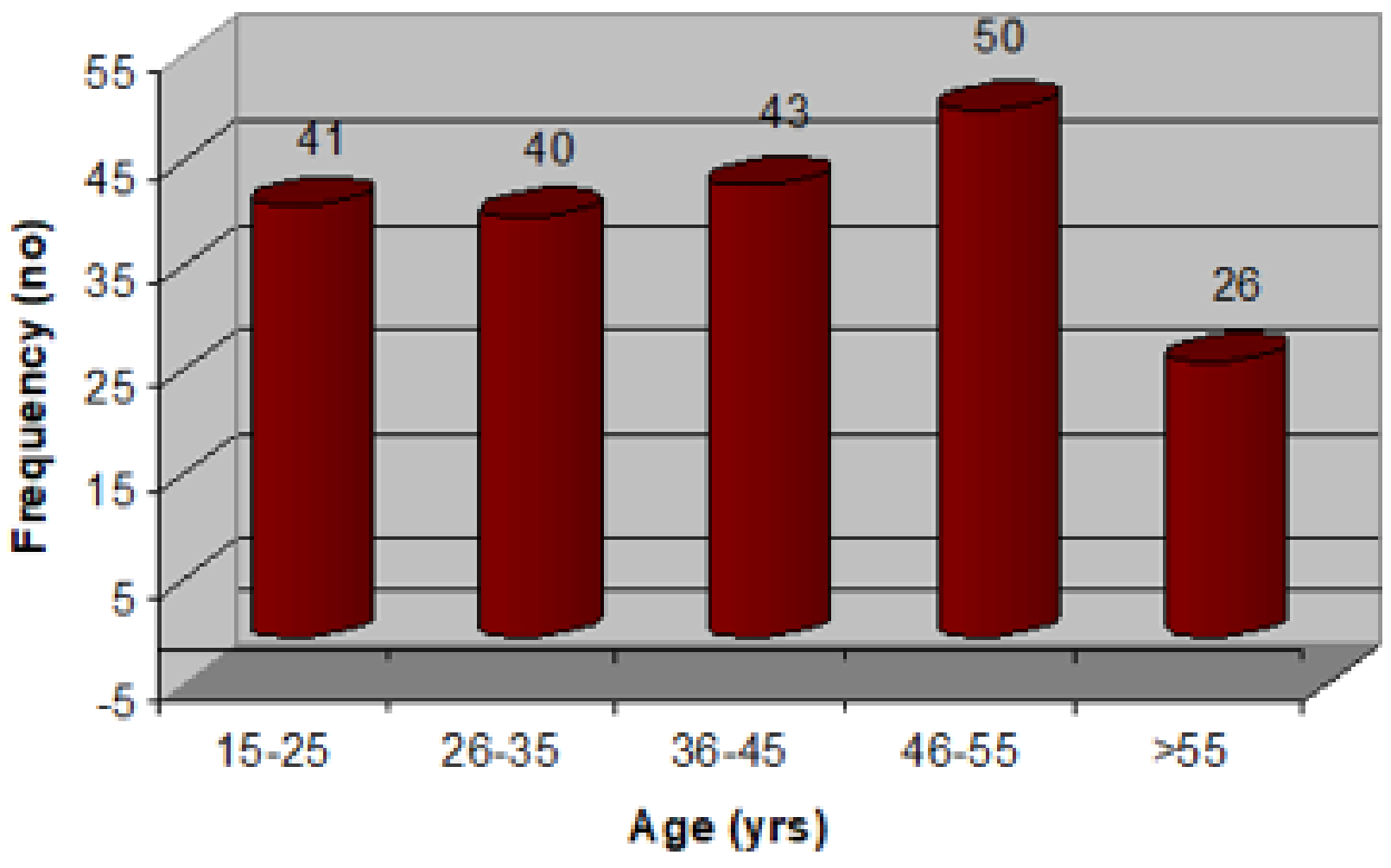


**Graph 1: Distribution of subjects According to age**

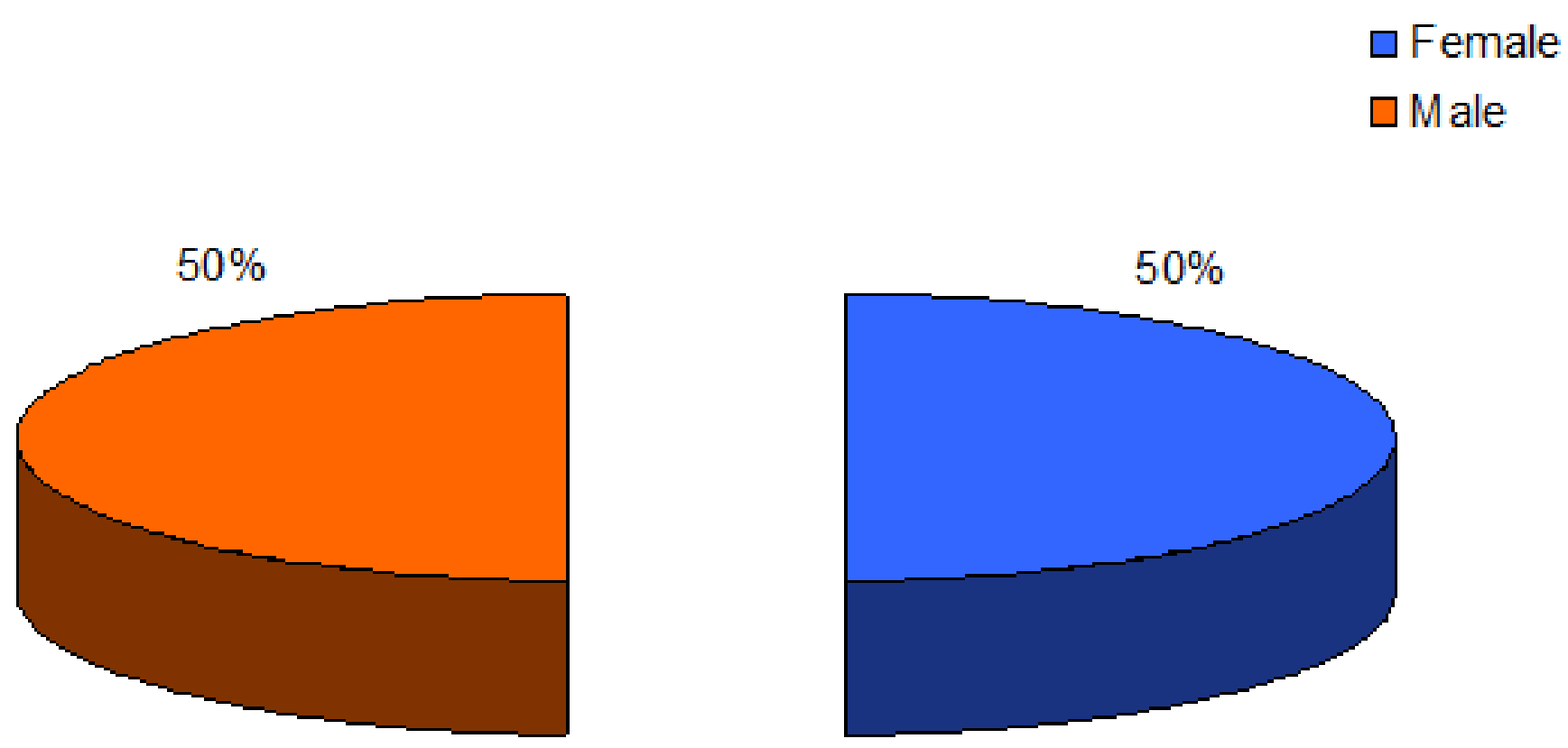


**Graph 2: Distribution of subjects according to gender**

The observation showed distribution of subjects according to age with 15-25 years were 41 (20.5%) 26-35 years were 40 (20.0%), 36-45 years were 43 (21.5%), 46-55 years were 50 (25.0%) and>55 years were 26 (13.0%) **(Table 1 and Graph 1);** distribution of subjects according to gender with 100 (50.0%) females and 100 (50.0%) males **(Table 1 and Graph 2).**

**Table 2: Comparison of frontal sinus among different age groups**

| Frontal sinus | 15-25 yrs (n=41) | 26-35 yrs (n=40) | 36-45 yrs (n=43) | 46-55 yrs (n=50) | >55 yrs (n=26) | F value | *P* value |
|---|---|---|---|---|---|---|---|
| Right length (mm) | 13.54 ± 4.14 | 12.66 ± 5.43 | 11.65 ± 3.25 | 12.35 ± 4.24 | 10.14 ± 1.07 | 3.16 | 0.015 |
| Right width (mm) | 19.46 ± 6.30 | 18.65 ± 7.26 | 19.77 ± 6.16 | 19.98 ± 7.45 | 12.60 ± 4.55 | 6.44 | <0.001 |
| Right area ($mm^2$) | 265.07 ± 143.07 | 248.45 ± 172.44 | 243.18 ± 131.20 | 261.97 ± 161.41 | 128.66 ± 50.53 | 4.52 | 0.002 |
| Left length (mm) | 14.41 ± 4.68 | 14.93 ± 6.62 | 13.34 ± 4.70 | 14.05 ± 4.70 | 13.09 ± 4.42 | 0.78 | 0.538 |
| Left width (mm) | 21.18 ± 7.89 | 21.32 ± 8.51 | 22.57 ± 8.10 | 21.84 ± 6.86 | 12.93 ± 3.68 | 8.23 | <0.001 |
| Left area ($mm^2$) | 311.38 ± 174.73 | 332.02 ± 217.89 | 312.76 ± 180.75 | 321.90 ± 191.68 | 169.63 ± 70.45 | 3.97 | 0.004 |

The observation shows distribution of the mean frontal sinus among different age groups (15- > 55 years). Right length with a mean value 3.16, right and left width with mean value 6.44 and 8.23 respectively, right and left area with a mean value 4.52 and 3.97 respectively which were significant ($P < 0.05$ or $P < 0.01$ or $P < 0.001$) and left length ($P > 0.05$) with mean value 0.78 was found to be not significant **(Table 2)**

**Table 3- Comparison and measurement of difference in mean frontal sinus between different age groups**

| Comparison-Age (yrs) | Right side of frontal sinus | | | | | | Left side of frontal sinus | | | | | |
|---|---|---|---|---|---|---|---|---|---|---|---|---|
| | Length (mm) | | Width (mm) | | Area ($mm^2$) | | Length (mm) | | Width (mm) | | Area ($mm^2$) | |
| | Mean diff | *P* value | Mean diff | *P* value | Mean diff | *P* value | Mean diff | *P* value | Mean diff | *P* value | Mean diff | *P* value |
| 15-25 vs. 26-35 | 0.88 | 0.865 | 0.81 | 0.982 | 16.61 | 0.985 | 0.51 | 0.991 | 0.14 | 1.000 | 20.64 | 0.986 |
| 15-25 vs. 36-45 | 1.89 | 0.202 | 0.32 | 0.999 | 21.88 | 0.957 | 1.07 | 0.873 | 1.40 | 0.910 | 1.38 | 1.000 |
| 15-25 vs. 46-55 | 1.19 | 0.632 | 0.52 | 0.996 | 3.09 | 1.000 | 0.36 | 0.997 | 0.66 | 0.993 | 10.52 | 0.999 |
| 15-25 vs. >55 | 3.40 | 0.007 | 6.85 | <0.001 | 136.40 | 0.001 | 1.33 | 0.839 | 8.25 | <0.001 | 141.75 | 0.015 |
| 26-35 vs. 36-45 | 1.01 | 0.785 | 1.12 | 0.937 | 5.27 | 1.000 | 1.58 | 0.620 | 1.26 | 0.939 | 19.27 | 0.989 |
| 26-35 vs. 46-55 | 0.31 | 0.996 | 1.33 | 0.878 | 13.52 | 0.992 | 0.88 | 0.928 | 0.52 | 0.997 | 10.12 | 0.999 |
| 26-35 vs. >55 | 2.52 | 0.096 | 6.05 | 0.003 | 119.79 | 0.009 | 1.84 | 0.609 | 8.39 | <0.001 | 162.39 | 0.003 |
| 36-45 vs. 46-55 | 0.71 | 0.919 | 0.20 | 1.000 | 18.79 | 0.971 | 0.71 | 0.964 | 0.73 | 0.990 | 9.15 | 0.999 |
| 36-45 vs. >55 | 1.51 | 0.560 | 7.17 | <0.001 | 114.52 | 0.012 | 0.26 | 1.000 | 9.65 | <0.001 | 143.13 | 0.012 |
| 46-55 vs. >55 | 2.22 | 0.156 | 7.37 | <0.001 | 133.31 | 0.001 | 0.96 | 0.936 | 8.91 | <0.001 | 152.27 | 0.005 |

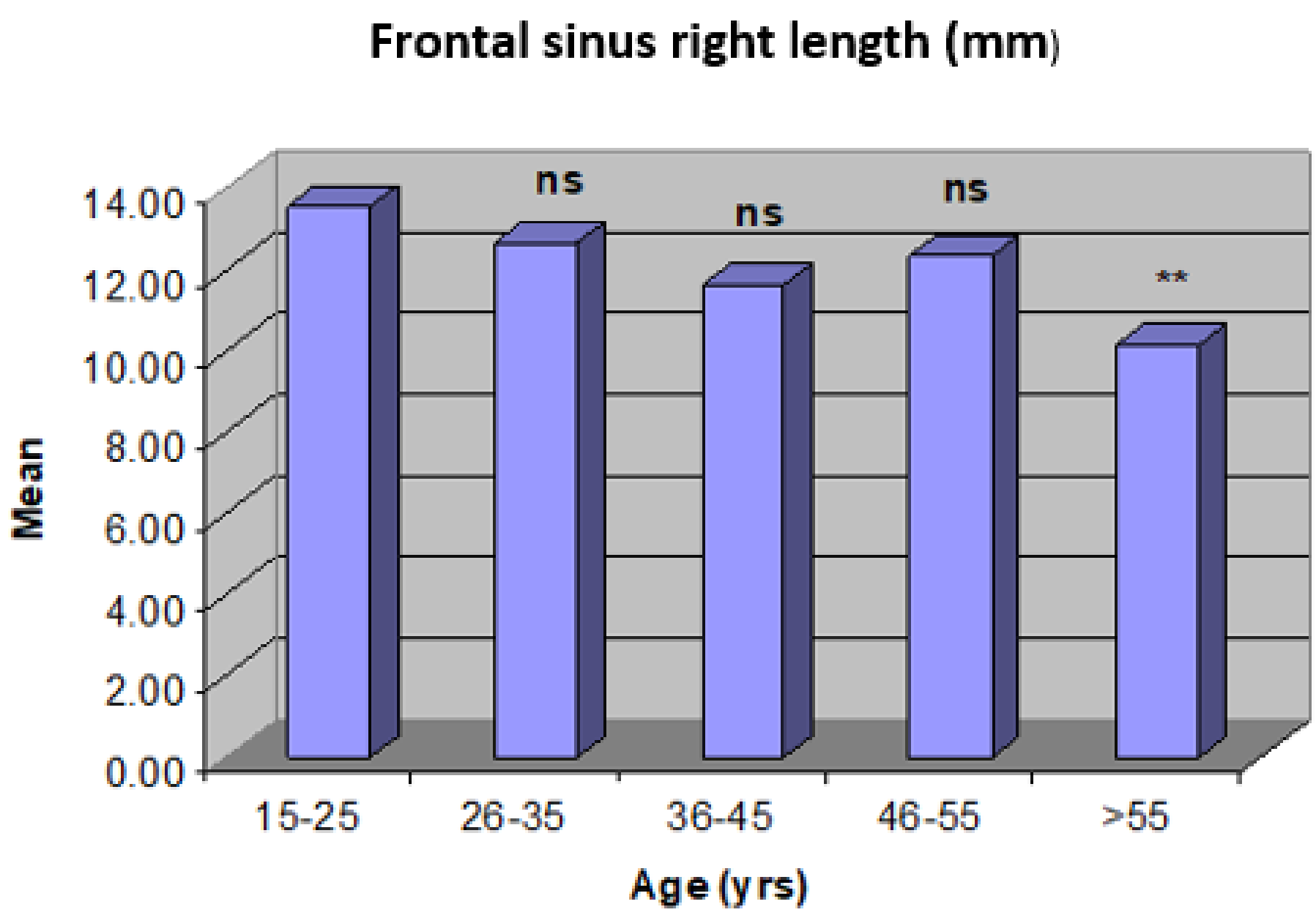


**Graph 3a- Comparison of difference in mean right frontal sinus length among different age groups**

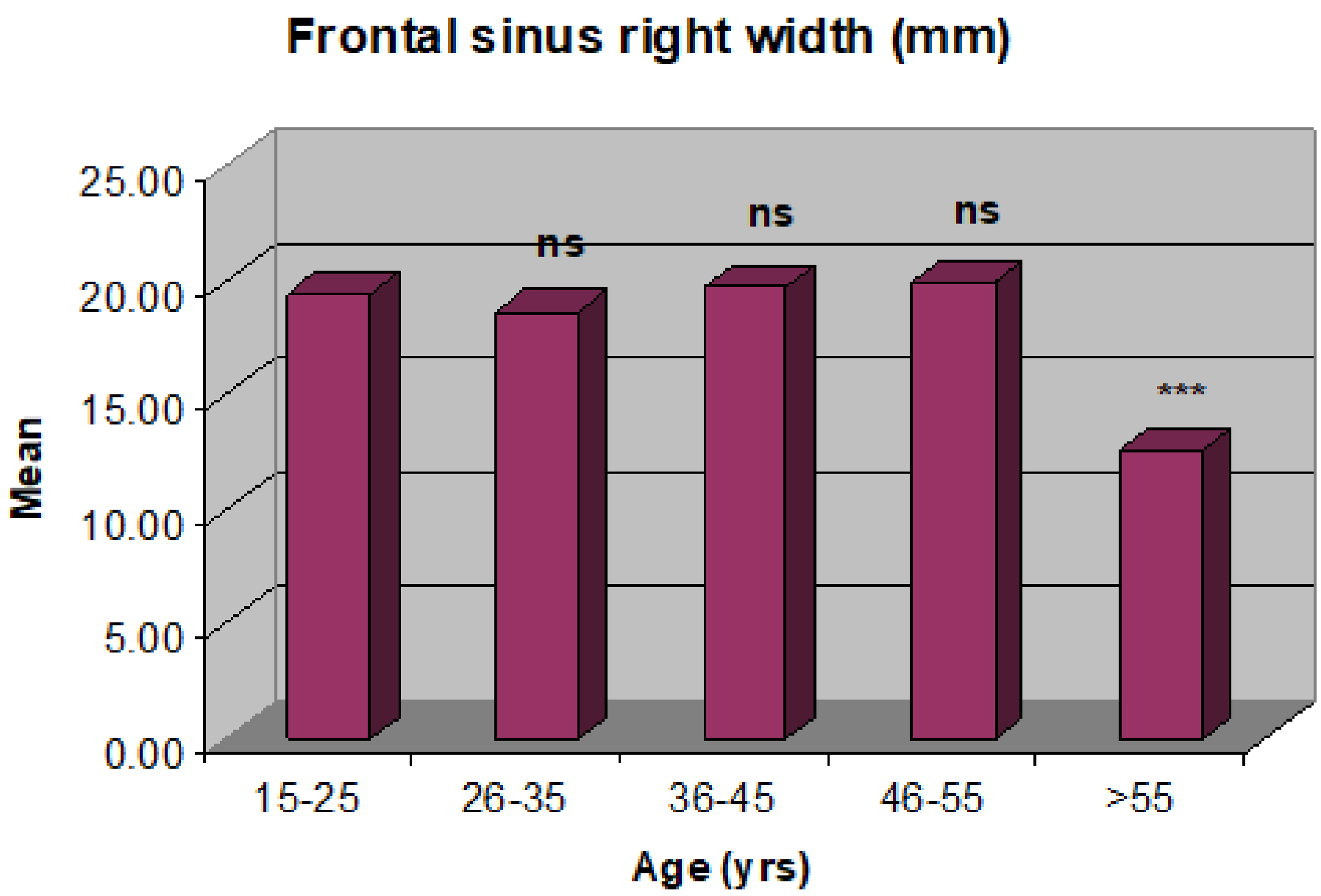


**Graph 3b- Comparison of difference in mean right frontal sinus width among different age groups**

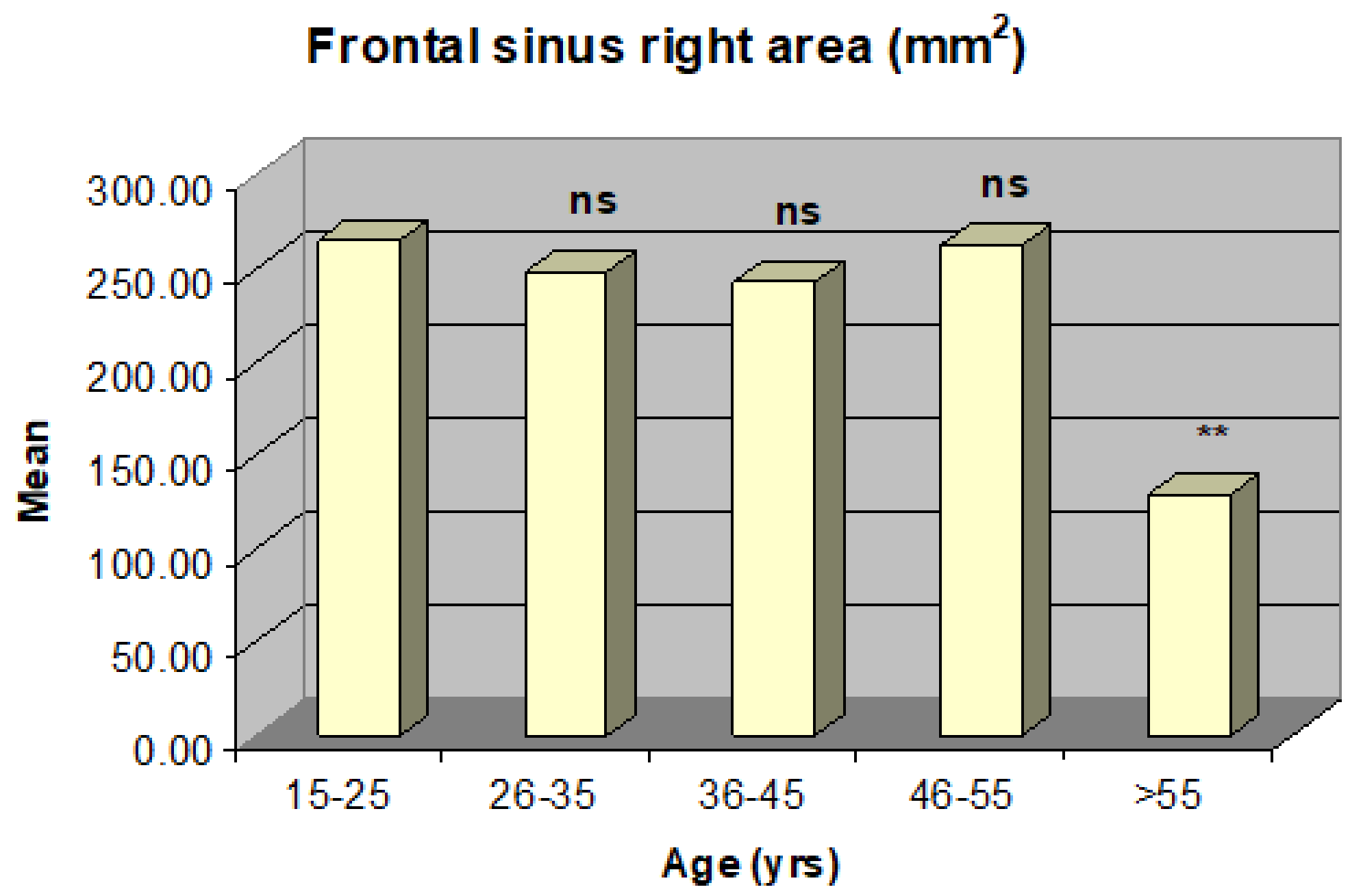


**graph 3c- Comparison of difference in mean right frontal sinus area among different age groups**

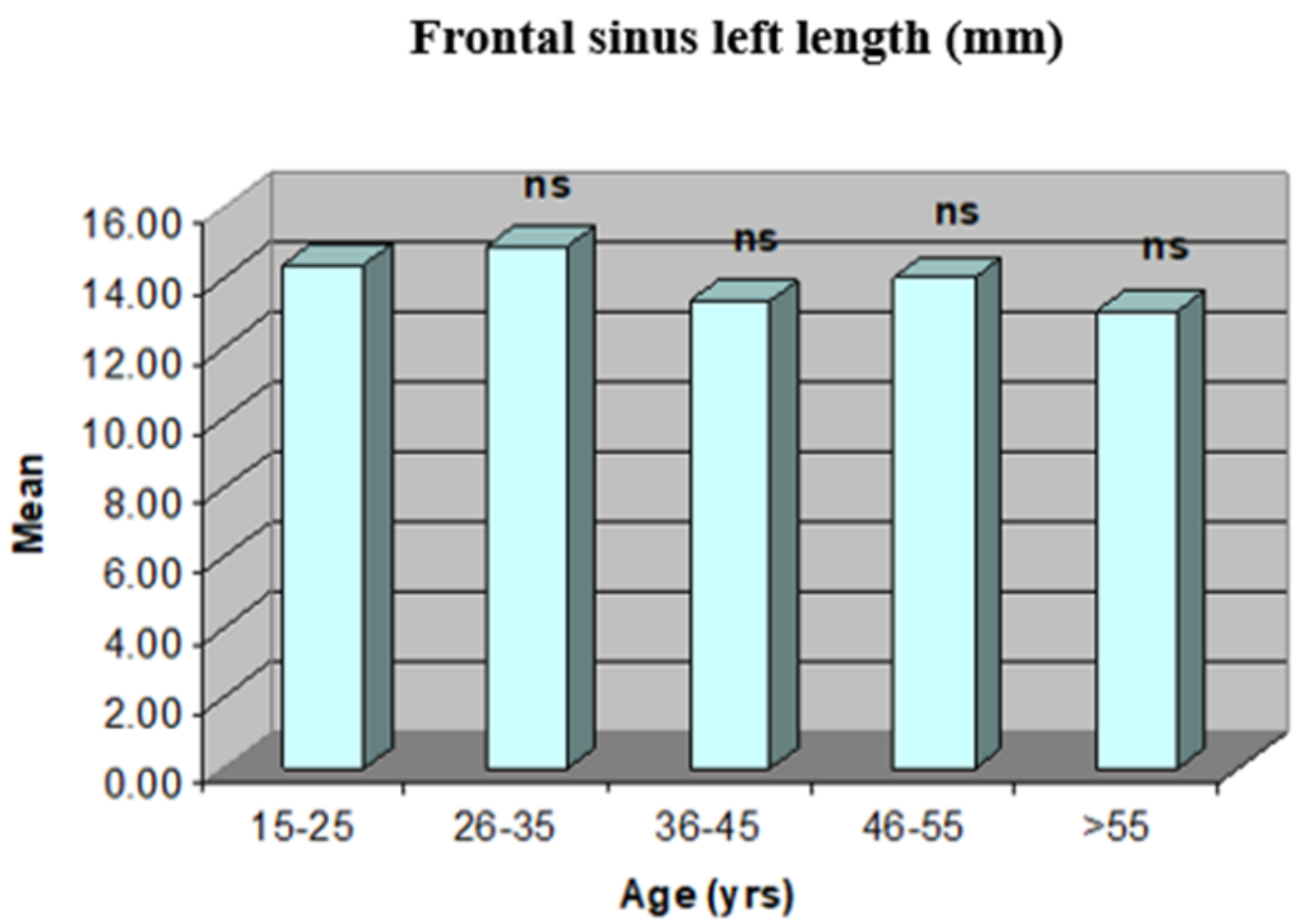


**Graph 3 d- Comparison of difference in mean left frontal sinus length among different age groups.**

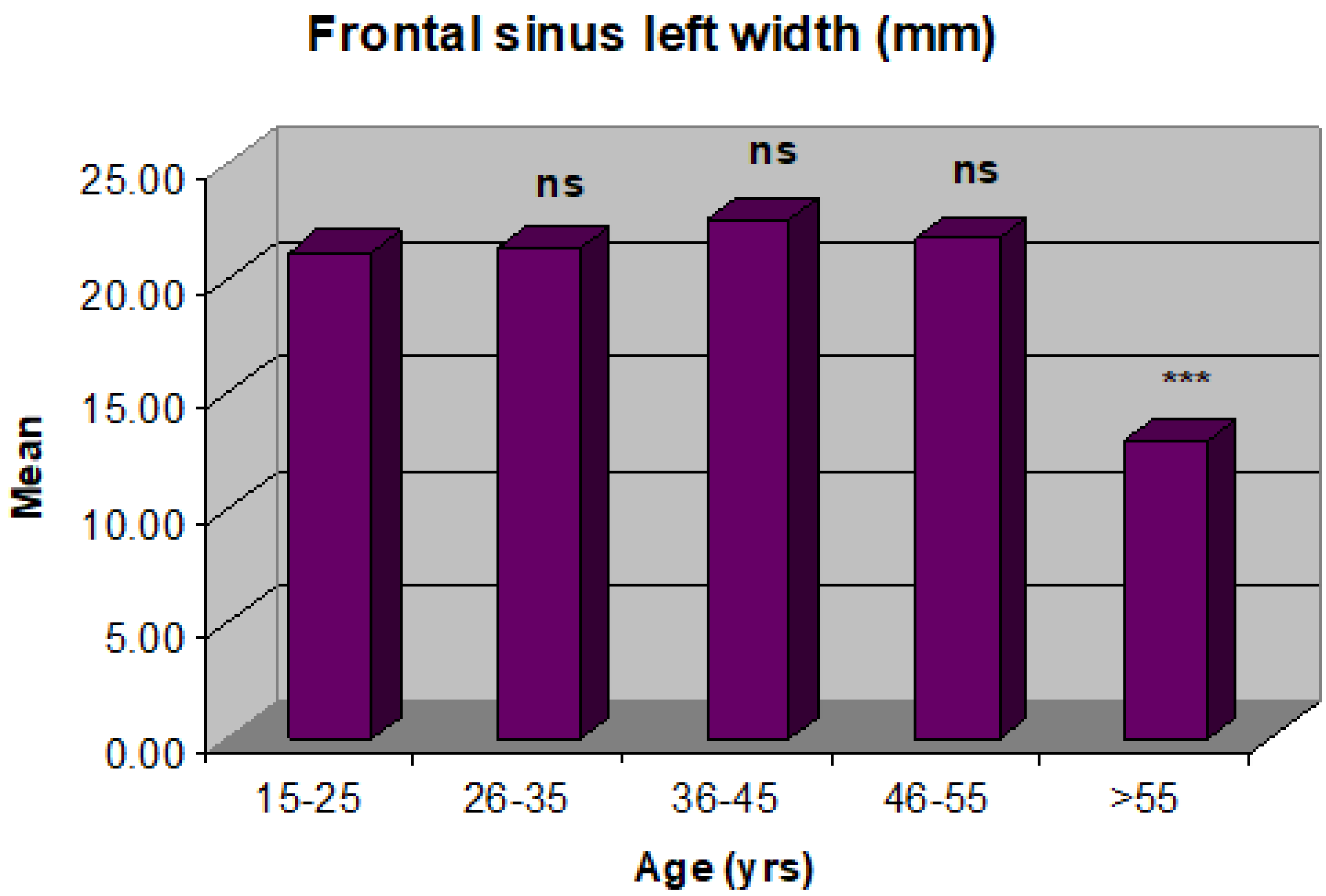


**Graph 3 e- Comparison of difference in mean left frontal sinus width among different age groups.**

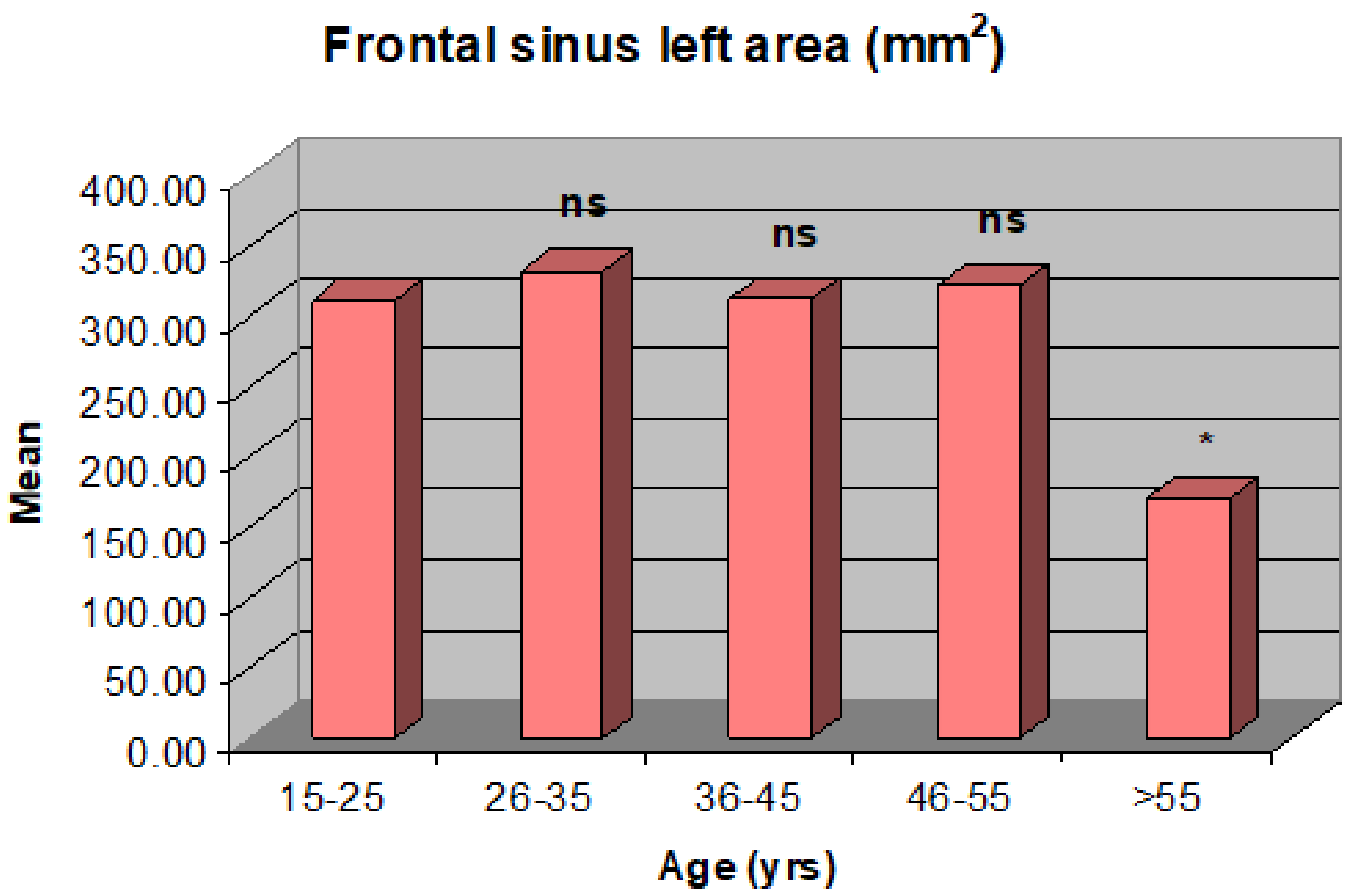


**Graph 3 f - Comparison of difference in mean left frontal sinus area among different age groups.**

The above observation in **Table 3** shows the comparison of difference in mean frontal sinus between different age groups (15- > 55 years). The result shows decrease in the right length **( graph 3 a)** with mean difference 3.40 mm which was significant (P <0.05) in age group > 55years as compared to 15- 55 years; there was decrease in right width **(graph 3 b)** with mean difference 6.85 mm which was significant ( p<0.01) in age group > 55 years as compared to 15- 55 years; a decrease was seen in frontal sinus right area **( graph 3 c)** with mean difference 136.40 mm in age group > 55 years as compared to 15- 55 years which was significant ( p <0 .001). Frontal sinus left width **(graph 3 e)** and left area **(graph 3 f)** also showed decrease in age group > 55 years as compared to 15- 55 years with mean differences of 8.25 and 141.75 mm respectively which was significant (p<0.001 and p<0.01). Frontal sinus left length **(graph 3 d)** showed no significant changes in age group (p >0.05) with mean difference 0.83 mm

**The mean frontal sinus varied with age. On an average it decreases with age**

**Table 4- Comparison of orbital aperture and inter orbital distance among different age groups**

| Orbital aperture | 15-25 yrs (n=41) | 26-35 yrs (n=40) | 36-45 yrs (n=43) | 46-55 yrs (n=50) | >55 yrs (n=26) | F value | *P* value |
|---|---|---|---|---|---|---|---|
| Right length (mm) | 32.51 ± 3.48 | 31.63 ± 2.80 | 32.79 ± 3.41 | 32.40 ± 3.28 | 31.98 ± 3.42 | 0.77 | 0.545 |
| Right width (mm) | 32.94 ± 2.33 | 33.78 ± 1.99 | 33.51 ± 2.37 | 33.21 ± 2.33 | 32.98 ± 2.57 | 0.91 | 0.458 |
| Left length (mm) | 31.73 ± 3.00 | 30.76 ± 3.06 | 31.70 ± 3.71 | 31.90 ± 3.43 | 30.82 ± 3.97 | 0.98 | 0.419 |
| Left width (mm) | 32.61 ± 1.81 | 32.56 ± 2.61 | 33.03 ± 2.27 | 33.22 ± 2.78 | 32.93 ± 3.08 | 0.55 | 0.700 |
| Interorbital distance (mm) | 24.61 ± 3.21 | 24.54 ± 2.62 | 24.26 ± 2.79 | 25.60 ± 2.46 | 25.13 ± 1.87 | 1.82 | 0.127 |

The above observation shows distribution of mean orbital aperture and interorbital distance among different age groups, right length with mean value 0.77 mm and width with mean value 0.91 mm, left length with mean value 0.98 mm and width with mean value 0.55 mm and interorbital distance with mean value 1.82 mm was not significant (P > 0.05) among the groups (Table 4).

**Table 5- Comparison and measurement of difference in mean orbital aperture and inter orbital distance between different age groups**

| Comparison-Age (yrs) | right side of orbital aperture | | | | left side of Orbital aperture | | | | Interorbital distance (mm) | |
|---|---|---|---|---|---|---|---|---|---|---|
| | Length (mm) | | Width (mm) | | Length (mm) | | Width (mm) | | | |
| | Mean diff | *P* value | Mean diff | *P* value | Mean diff | *P* value | Mean diff | *P* value | Mean diff | *P* value |
| 15-25 vs. 26-35 | 0.88 | 0.746 | 0.84 | 0.475 | 0.97 | 0.706 | 0.05 | 1.000 | 0.07 | 1.000 |
| 15-25 vs. 36-45 | 0.28 | 0.995 | 0.57 | 0.790 | 0.02 | 1.000 | 0.42 | 0.940 | 0.35 | 0.974 |
| 15-25 vs. 46-55 | 0.12 | 1.000 | 0.27 | 0.981 | 0.17 | 0.999 | 0.61 | 0.778 | 0.99 | 0.393 |
| 15-25 vs. >55 | 0.53 | 0.968 | 0.04 | 1.000 | 0.91 | 0.823 | 0.32 | 0.987 | 0.52 | 0.939 |
| 26-35 vs. 36-45 | 1.16 | 0.491 | 0.27 | 0.984 | 0.94 | 0.717 | 0.47 | 0.916 | 0.28 | 0.990 |
| 26-35 vs. 46-55 | 0.76 | 0.808 | 0.57 | 0.776 | 1.14 | 0.511 | 0.66 | 0.731 | 1.07 | 0.325 |
| 26-35 vs. >55 | 0.35 | 0.993 | 0.80 | 0.644 | 0.05 | 1.000 | 0.37 | 0.978 | 0.59 | 0.904 |
| 36-45 vs. 46-55 | 0.40 | 0.978 | 0.30 | 0.972 | 0.20 | 0.999 | 0.19 | 0.996 | 1.35 | 0.108 |
| 36-45 vs. >55 | 0.81 | 0.859 | 0.53 | 0.887 | 0.89 | 0.833 | 0.10 | 1.000 | 0.87 | 0.683 |
| 46-55 vs. >55 | 0.41 | 0.986 | 0.23 | 0.994 | 1.09 | 0.680 | 0.29 | 0.989 | 0.48 | 0.947 |

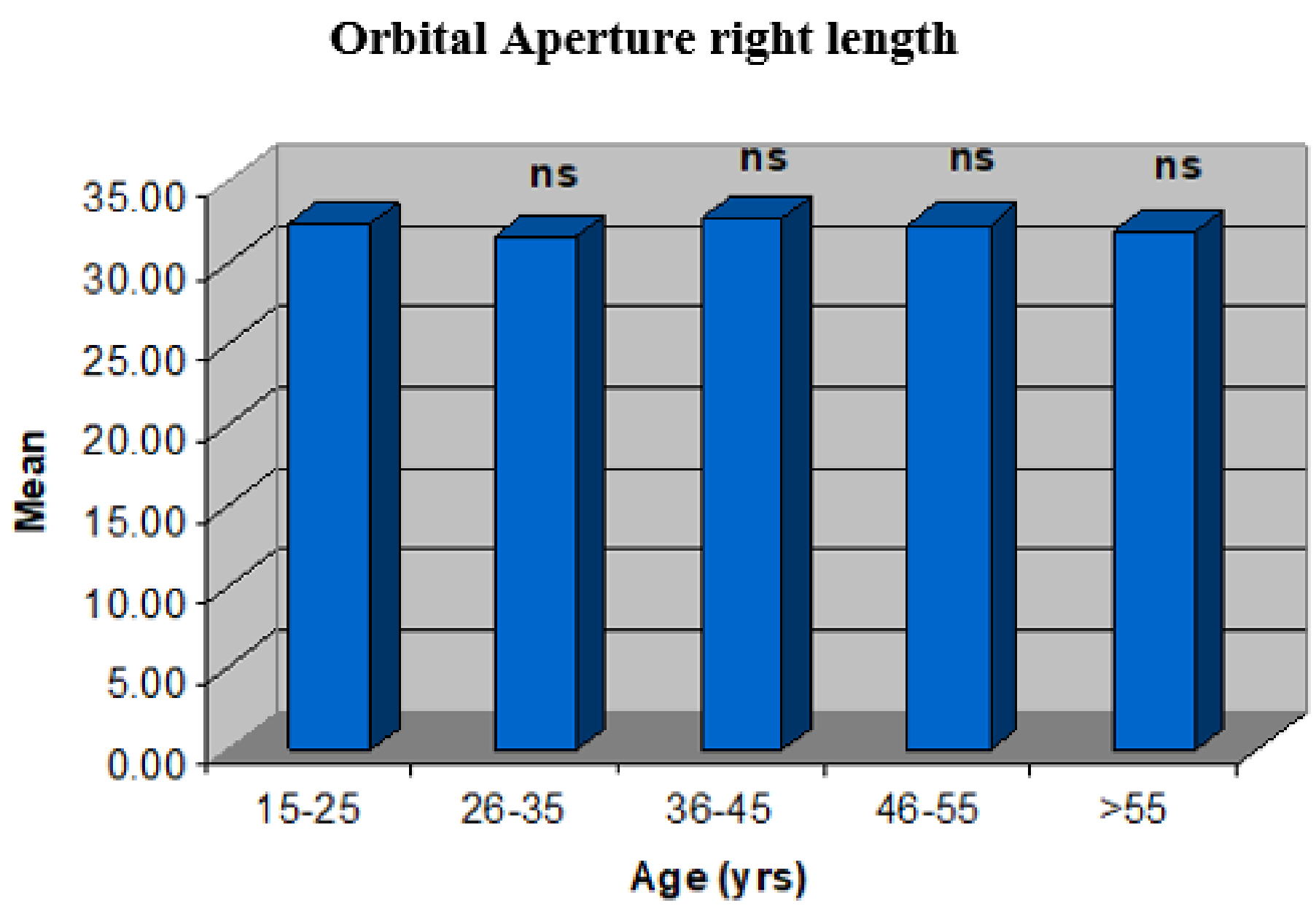


**Graph 5 a . Comparison of difference in mean right orbital aperture length among different age groups**

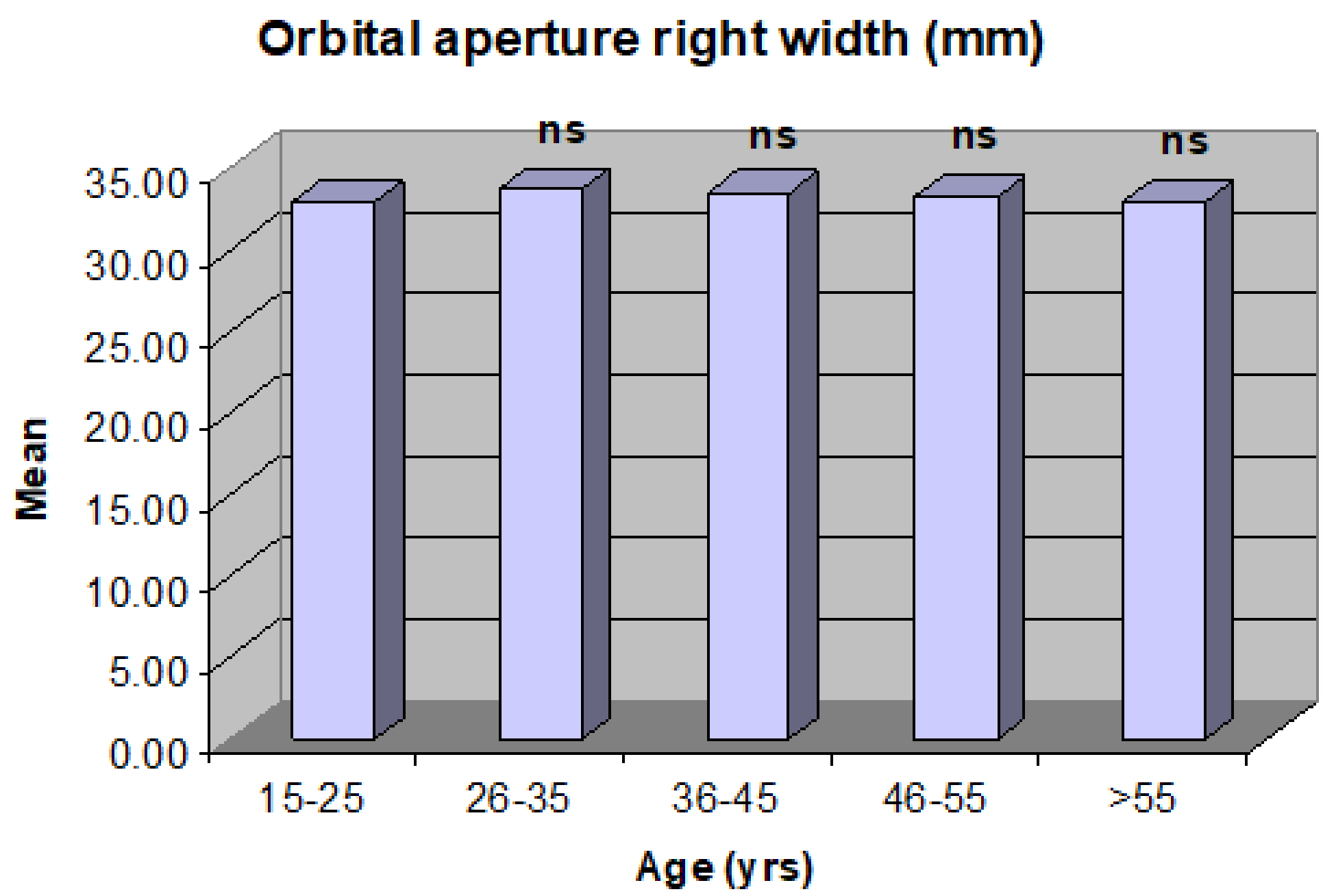


**Graph 5b . Comparison of difference in mean right orbital aperture width among different age groups.**

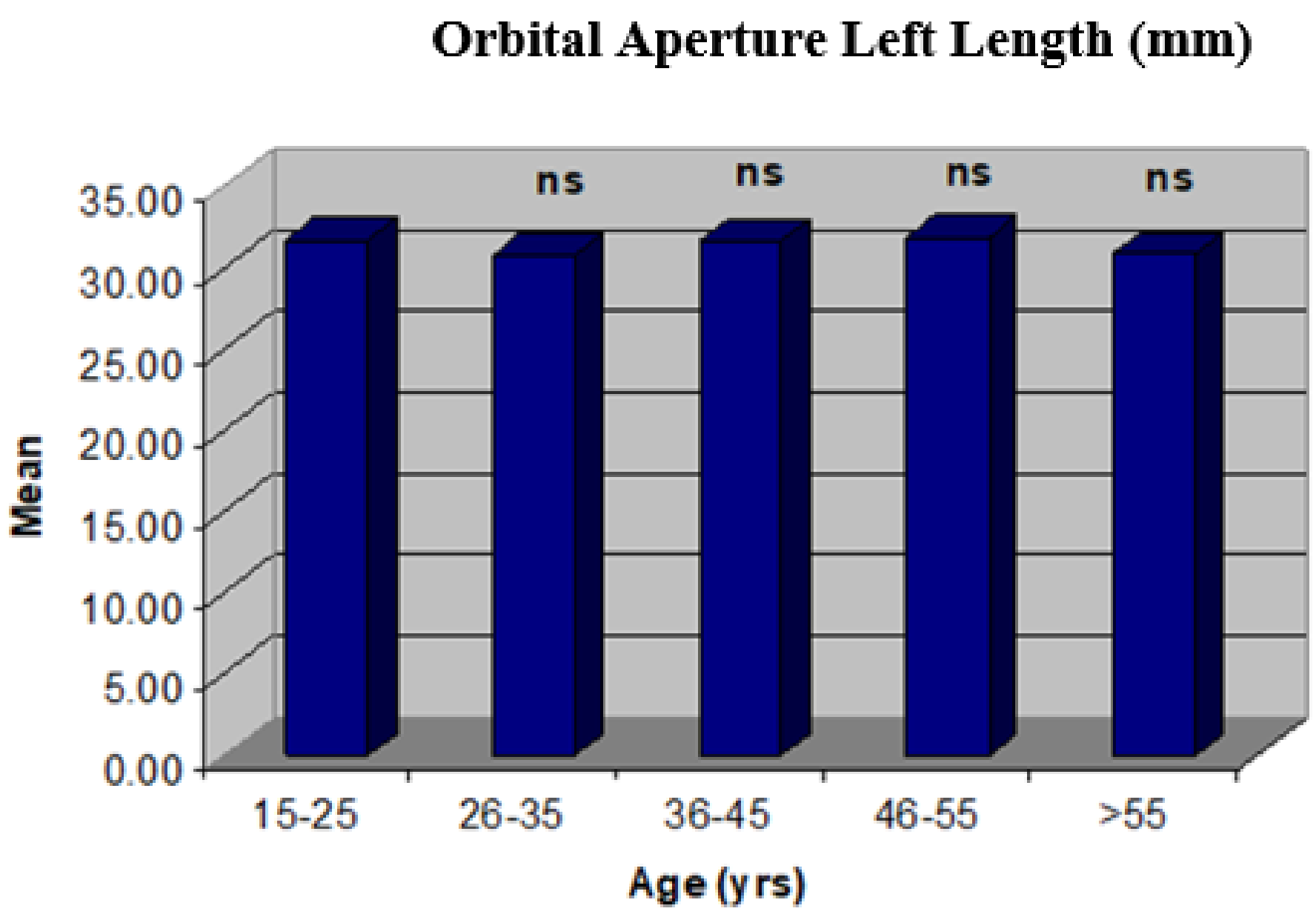


**Graph 5 c. Comparison of difference in mean left orbital aperture length among different age groups.**

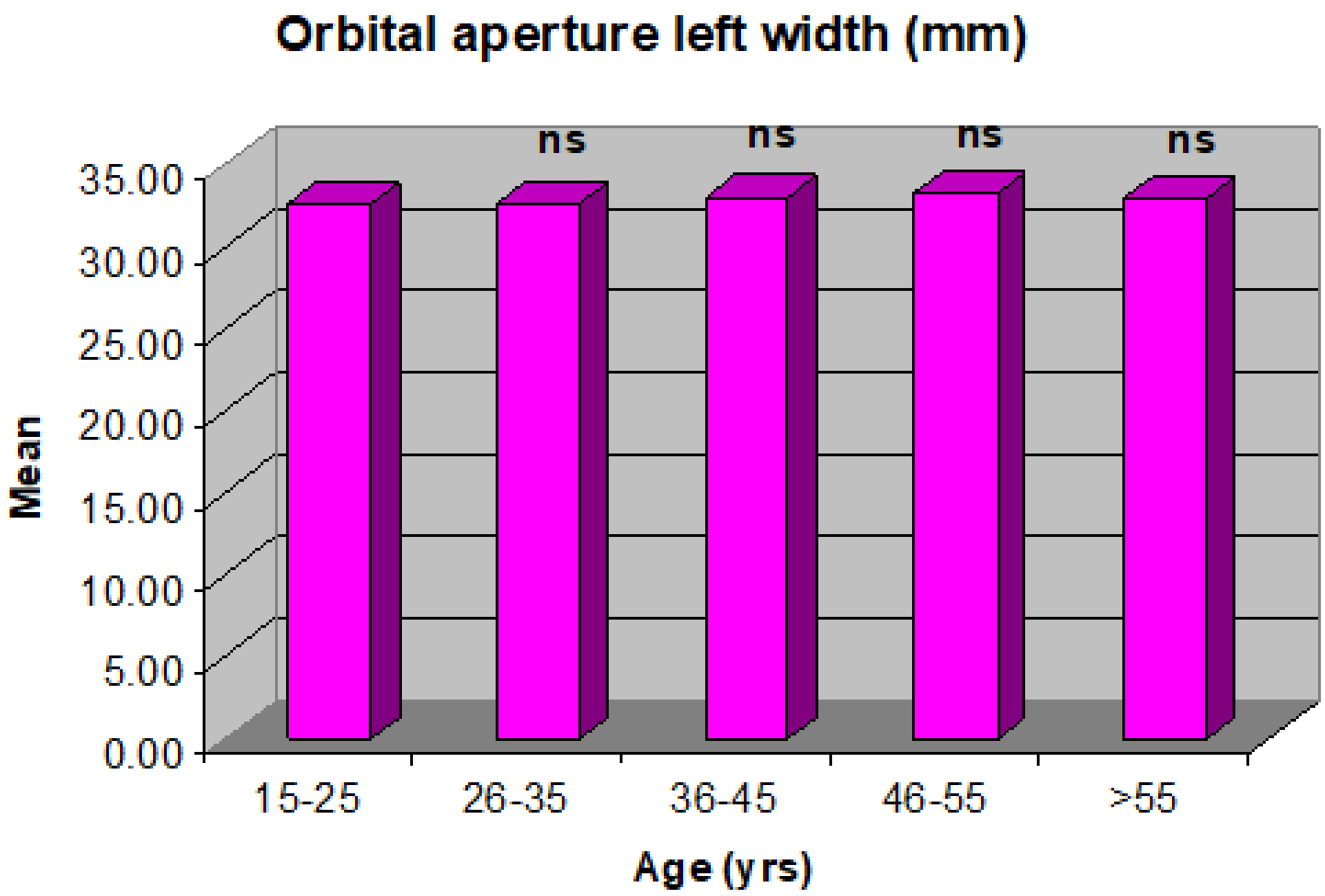


**Graph 5d . Comparison of difference in mean left orbital aperture width among different age groups.**

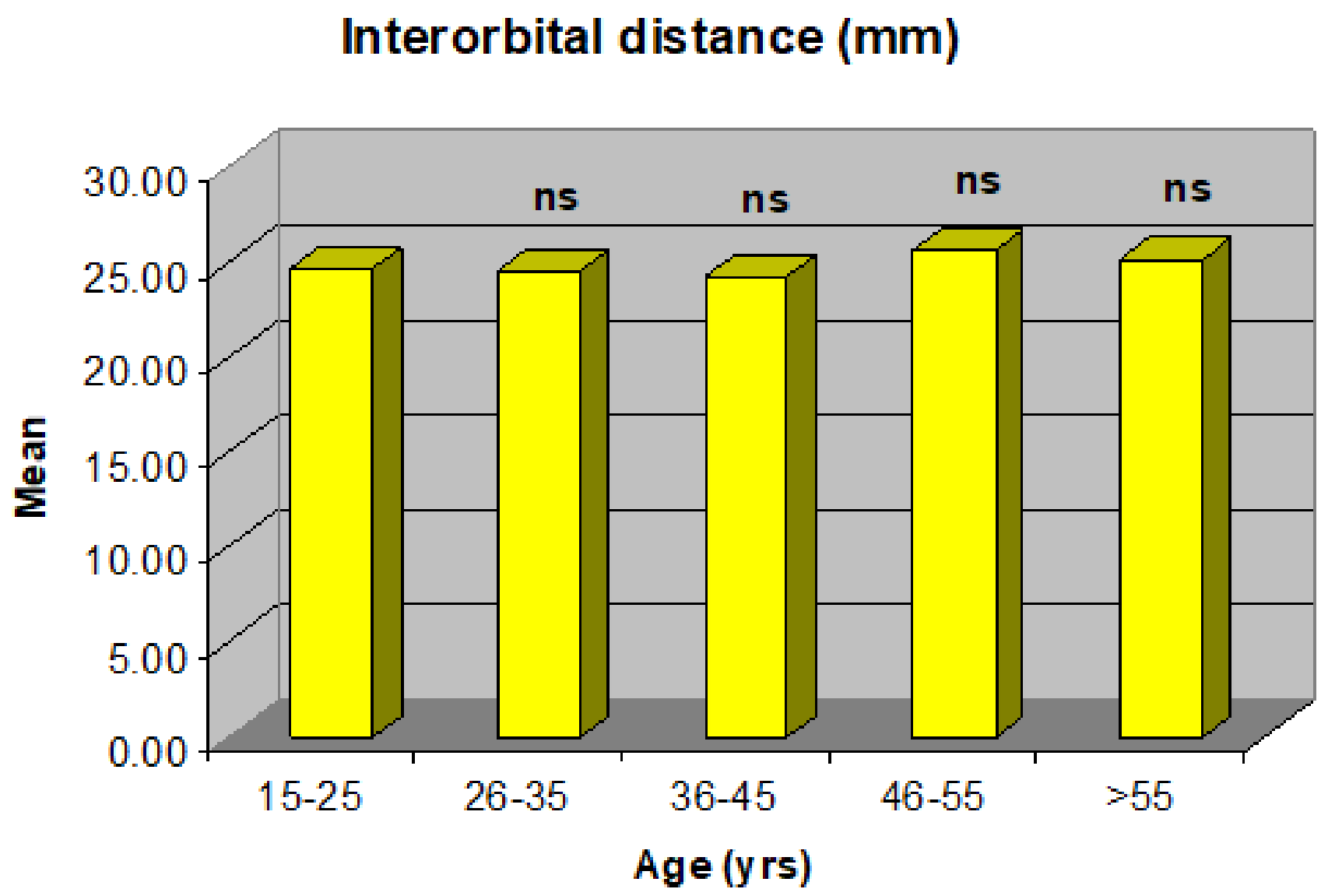


**Graph 5 e . Comparison of difference in mean interorbital distance among different age groups.**

The above observation in **table 5** shows the comparison of the difference in mean orbital aperture and interorbital distance between the different age groups (i.e. inter groups), the right orbital aperture length **(graph 5 a**) in age group of 15- 55 years as compared to > 55 years with mean difference 0.53 mm showed no significant changes ( $p > 0.05$); right orbital aperture width **( graph 5 b)** in age group of 15- 55 years as compared to > 55 years with mean difference 0.04 mm showed no significant changes ($p>0.05$) ; left orbital aperture length **(graph 5 c)** with mean difference 0.91 mm showed no significant changes ( p. 0.05); left orbital aperture width **( graph 5 d)** in the age group 15- 55 years as compared to > 55 years also showed no significant changes ( $p> 0.05$); inter-orbital distance **( graph 5 e)** in age group of 15- 55 years as compared to > 55 years showed no significant changes ($p>0.05$)

**The mean orbital aperture and inter orbital distance did not vary with age. On an average it remains similar among the age.**

**Table 6: Comparison of frontal sinus between both genders**

| Frontal sinus | Female (n=100) | Male (n=100) | Mean diff | t value | *P* value |
|---|---|---|---|---|---|
| Right length (mm) | 11.96 ± 3.65 | 12.47 ± 4.57 | 0.51 | 0.87 | 0.385 |
| Right width (mm) | 16.03 ± 6.24 | 21.18 ± 6.67 | 5.15 | 5.64 | <0.001 |
| Right area ($mm^2$) | 201.39 ± 125.90 | 275.67 ± 161.18 | 74.28 | 3.63 | <0.001 |
| Left length (mm) | 13.00 ± 4.26 | 15.05 ± 5.65 | 2.05 | 2.90 | 0.004 |
| Left width (mm) | 17.67 ± 6.39 | 23.53 ± 8.27 | 5.86 | 5.61 | <0.001 |
| Left area ($mm^2$) | 239.86 ± 136.82 | 360.16 ± 208.69 | 120.30 | 4.82 | <0.001 |

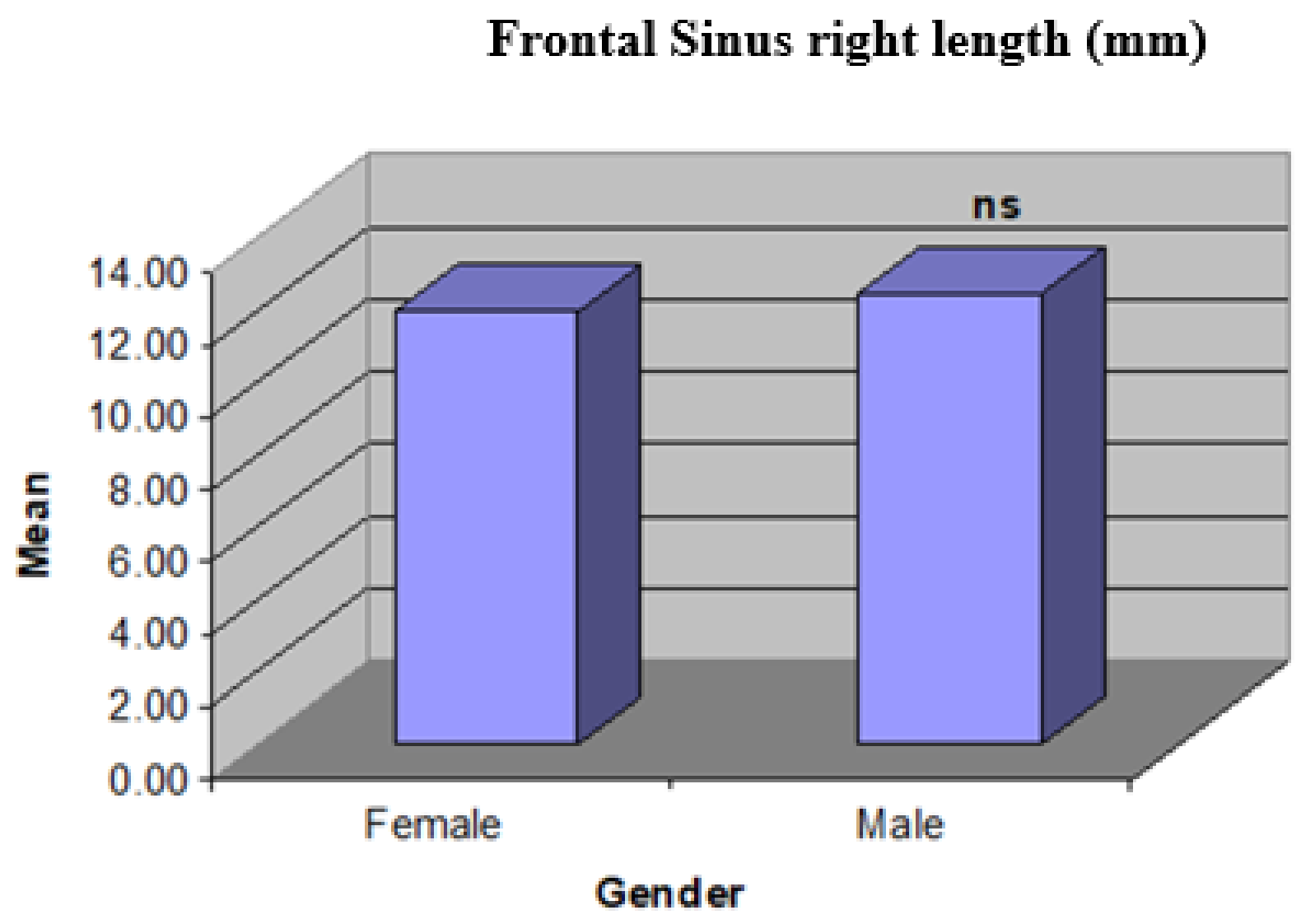


**Graph 6 a . Comparison of difference in mean right frontal sinus length between both genders**

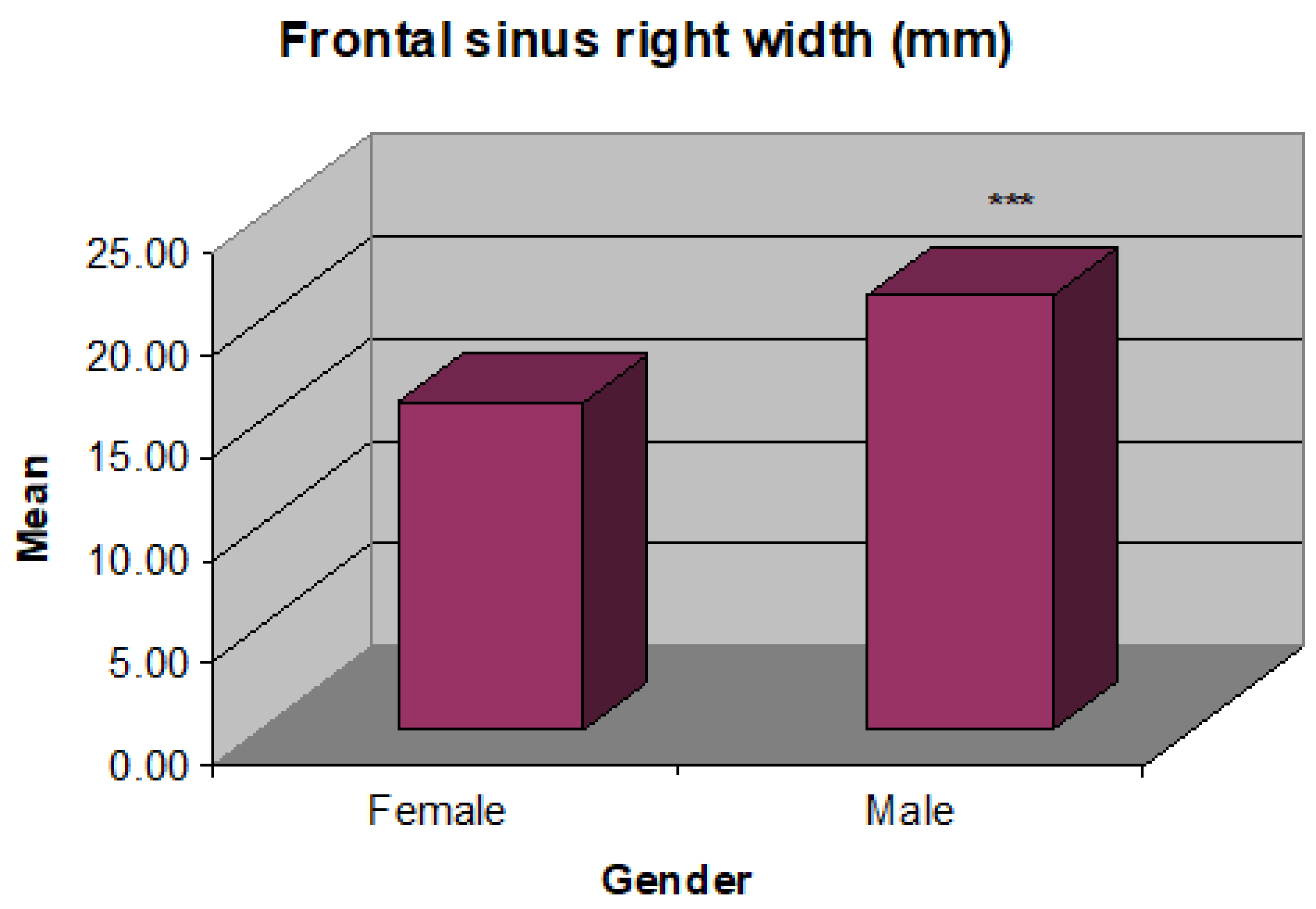


**Graph 6b . Comparison of difference in mean right frontal sinus width between two gender groups.**

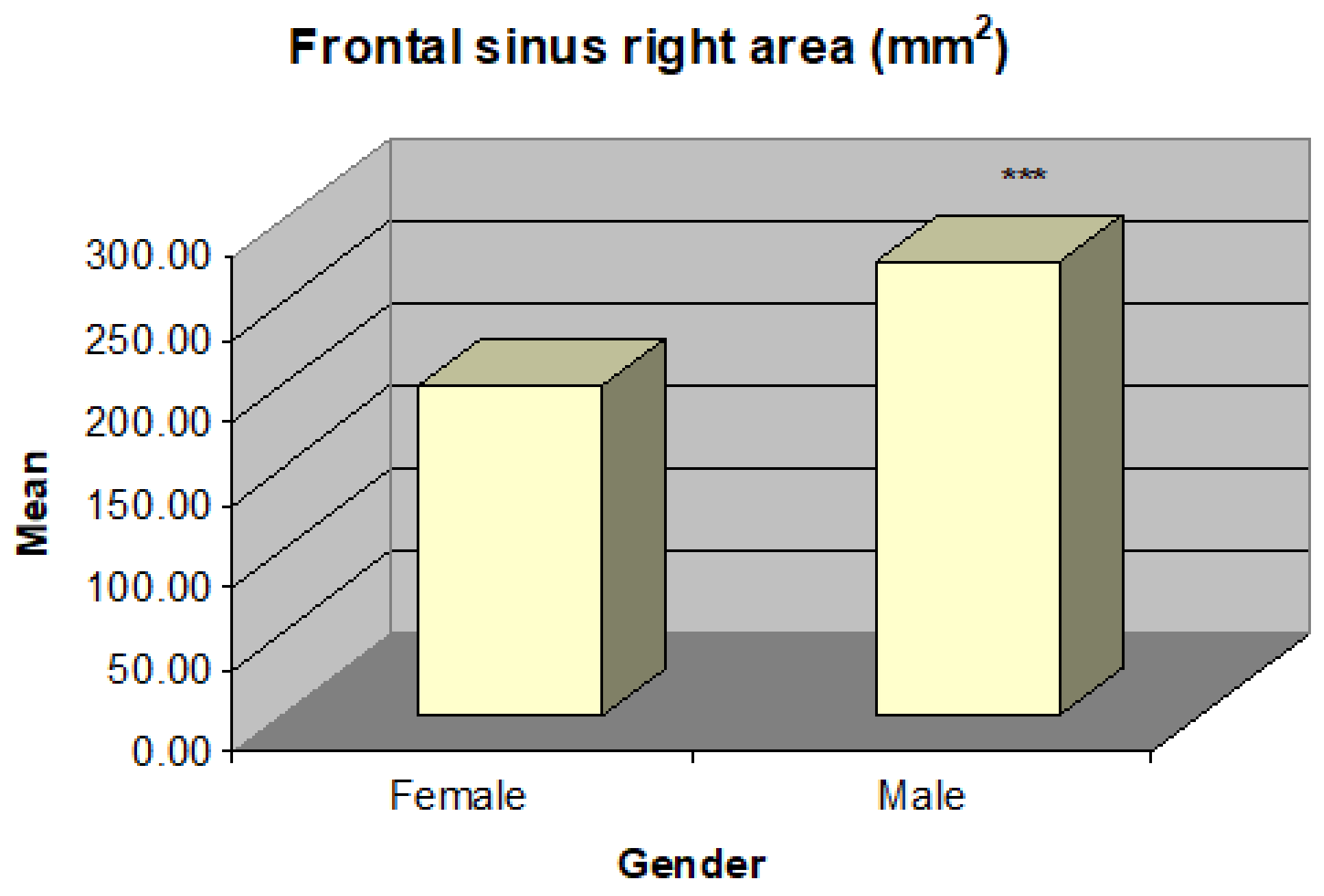


**Graph 6 c. Comparison of difference in mean right area of frontal sinus between two gender groups.**

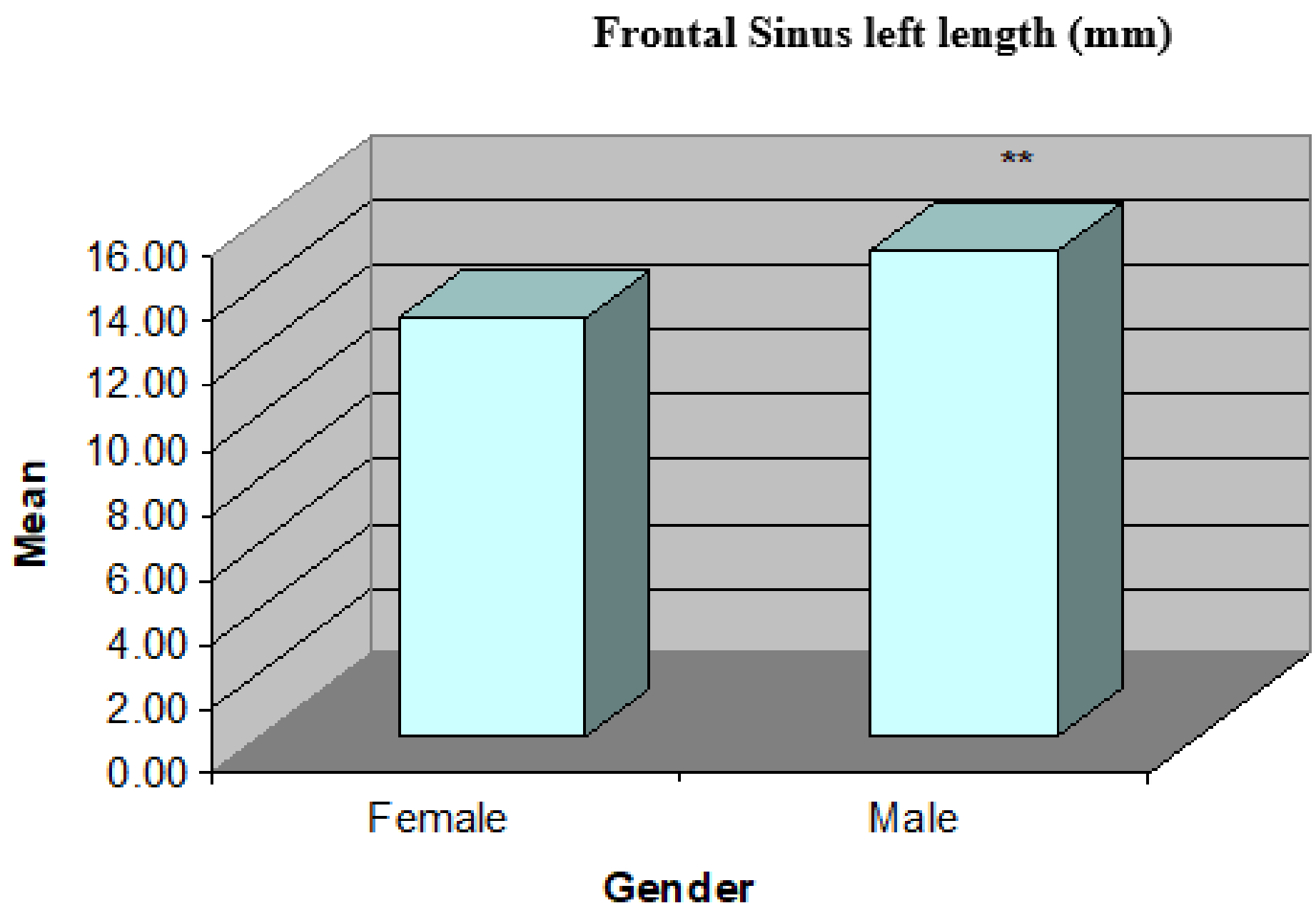


**Graph 6 d. Comparison of difference in mean frontal sinus left length between two gender groups.**

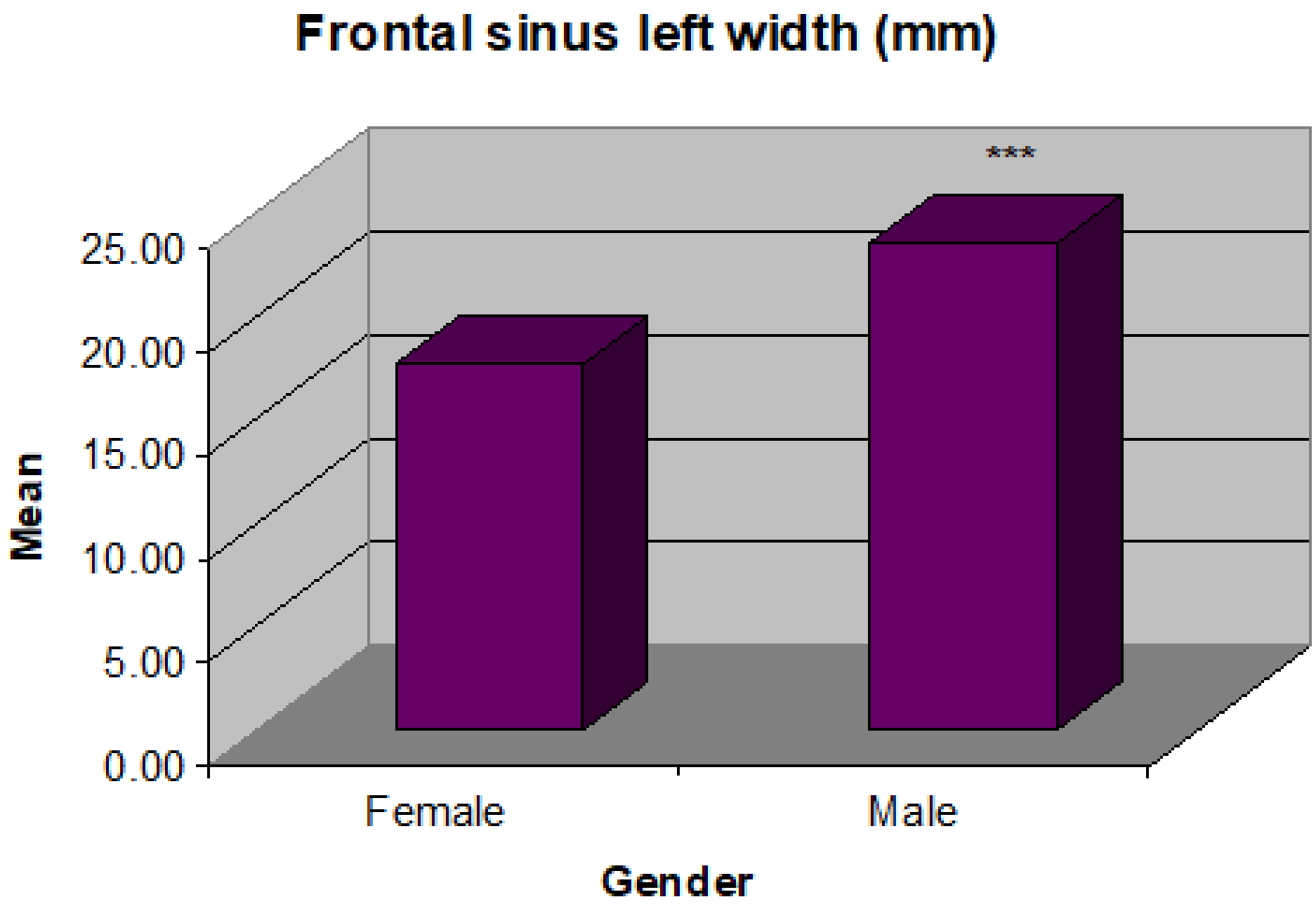


**Graph 6 e. Comparison of difference in mean frontal sinus left width between two gender groups.**

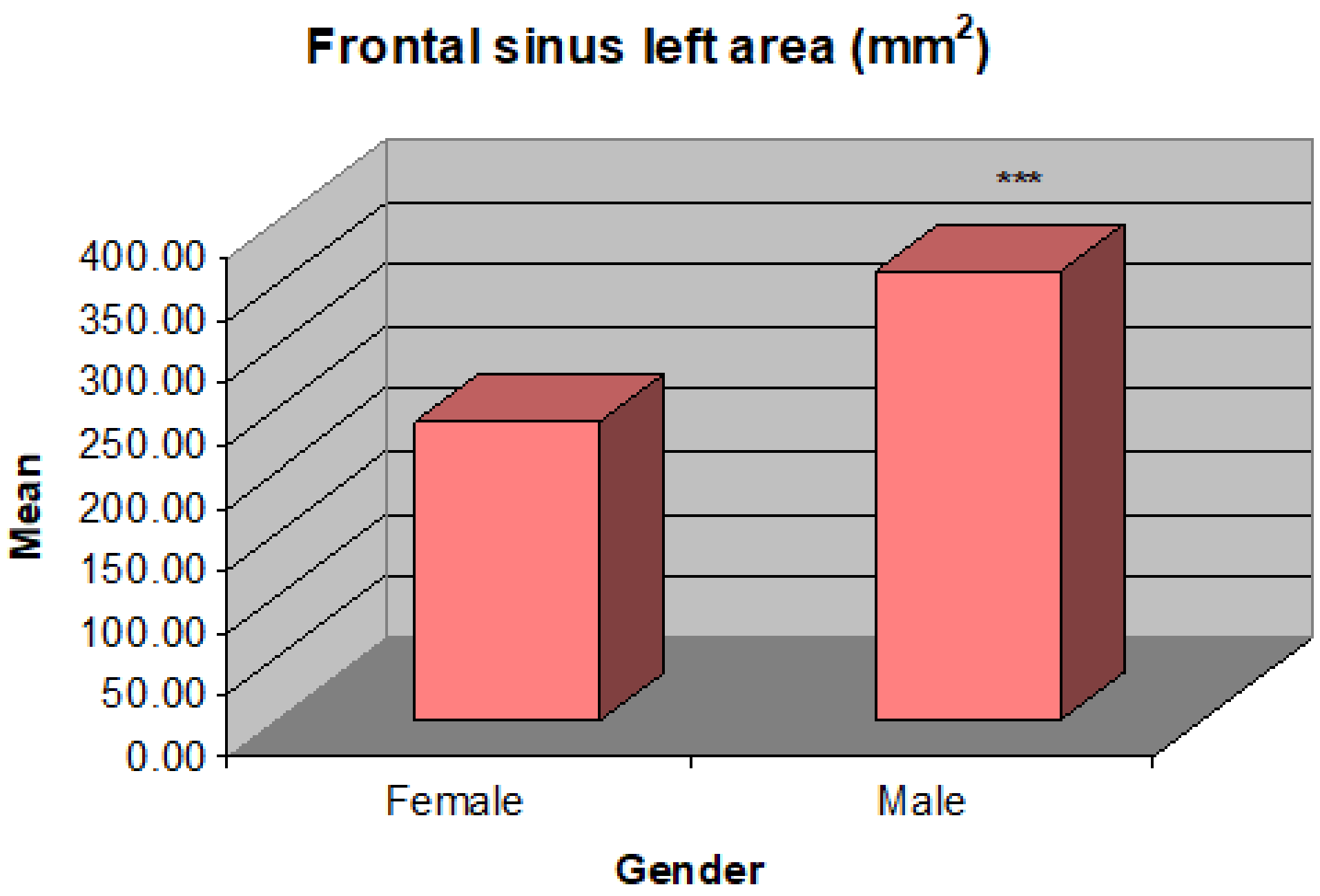


**Graph 6 f . Comparison of difference in mean left area of frontal sinus between two gender groups.**

The above observation in **table 6** shows the Comparison of difference in mean frontal sinus between both genders. Right width **(graph 6 b)** in males with mean deviation 21.18 ± 6.67 was higher than in females with mean deviation 16.03 ± 6.24 was found significant ($p < 0.001$). Right area **(graph 6 c)** in males with mean deviation 275.67 ± 161.18 was higher than in females with mean deviation 201.39 ± 125.90 was found to be significant ($p < 0.001$). left length **(graph 6 d)** in males with mean deviation 15.05 ± 5.65 was found to be higher than females with mean deviation 13.00 ± 4.26 was found to be significant ($p < 0.01$). left width **(graph 6 e)** in males with mean deviation 23.53 ± 8.27 was found to be higher than females with mean deviation 17.67 ± 6.39 was found to be significant ($p < 0.001$). left area **(graph 6 f)** in males with mean deviation 360.16 ± 208.69 was found to be higher than females with mean deviation 239.86 ± 136.82 was found to be significant ($p < 0.001$). The mean frontal sinus right length**(graph 6 a)** was found to be not significant ($P > 0.05$) , it was similar in both genders.

**The mean frontal sinus area varied with gender. The mean frontal sinus area was comparatively higher in males as compared to females**.

**Table 7: Distribution and comparison of orbital aperture and inter orbital distance between both genders**

| Orbital aperture | Female (n=100) | Male (n=100) | Mean diff | t value | *P* Value |
|---|---|---|---|---|---|
| Right length (mm) | 30.86 ± 3.34 | 33.74 ± 2.49 | 2.88 | 6.91 | <0.001 |
| Right width (mm) | 32.62 ± 2.18 | 33.99 ± 2.24 | 1.37 | 4.37 | <0.001 |
| Left length (mm) | 30.51 ± 3.35 | 32.40 ± 3.23 | 1.88 | 4.05 | <0.001 |
| Left width (mm) | 32.10 ± 2.43 | 33.66 ± 2.34 | 1.56 | 4.63 | <0.001 |
| Interorbital distance (mm) | 24.85 ± 2.80 | 24.82 ± 2.60 | 0.03 | 0.09 | 0.927 |

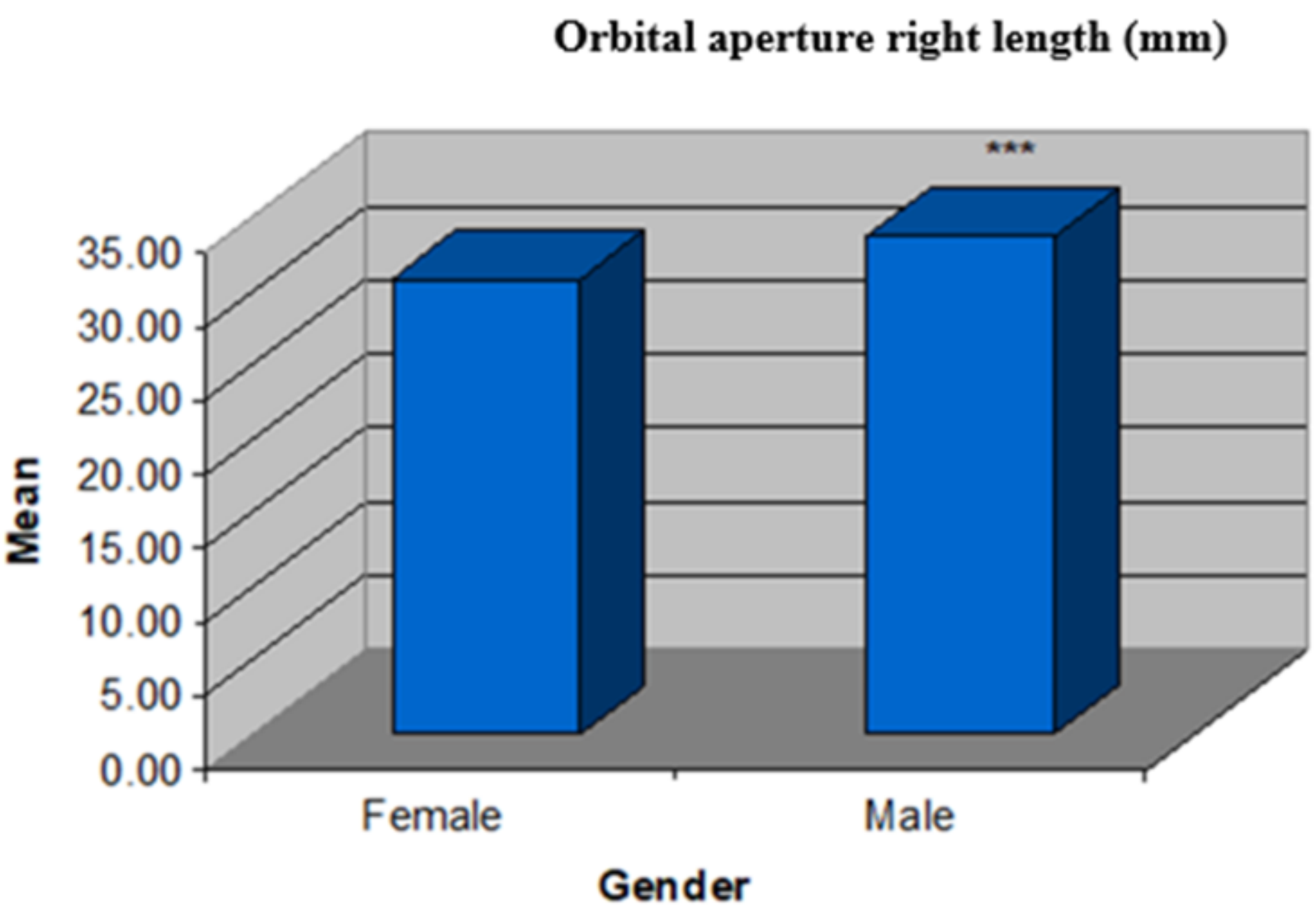


**Graph 7 a . Comparison of difference in mean right orbital aperture length between two gender groups**

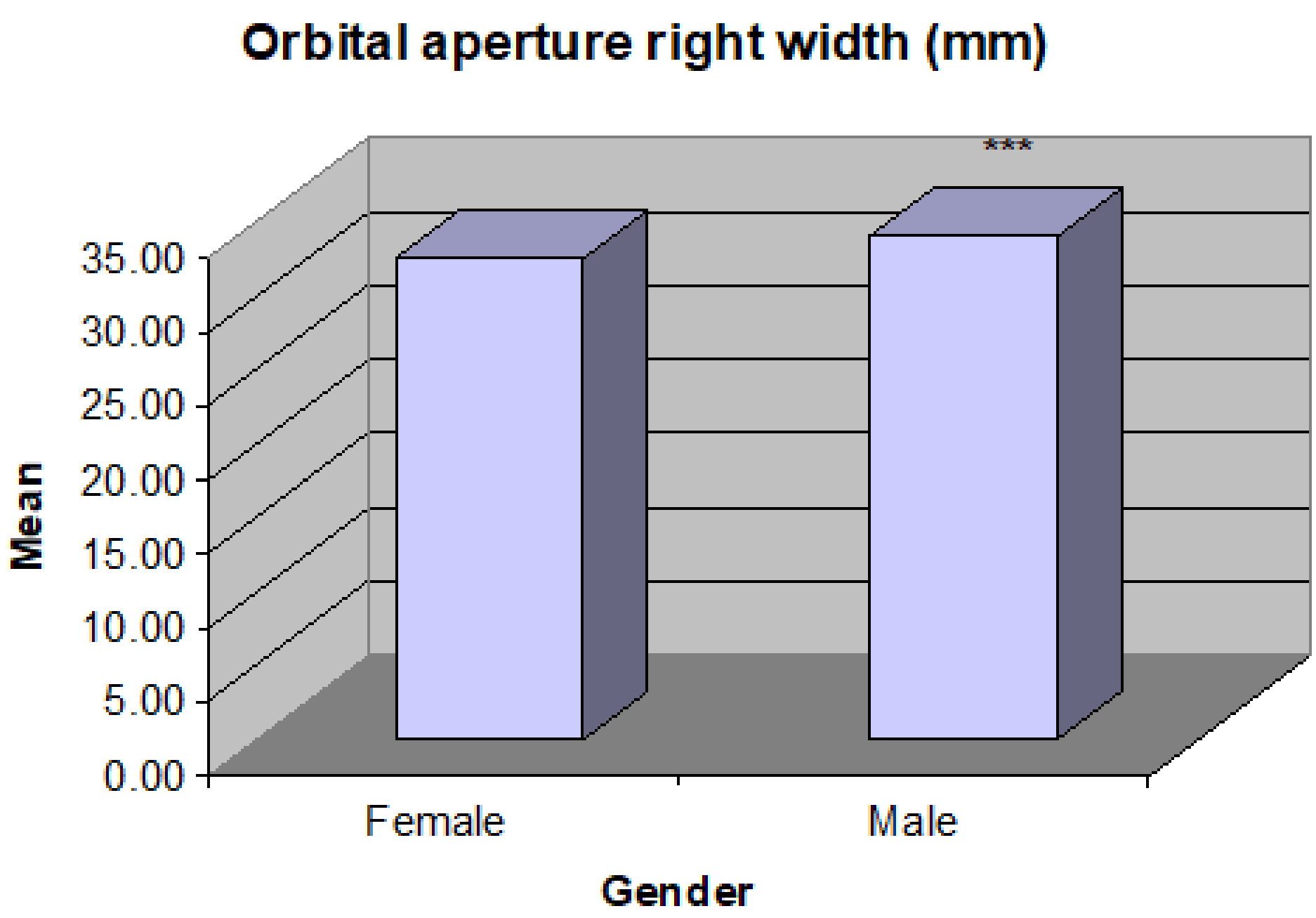


**Graph 7 b. Comparison of difference in mean right orbital aperture width between two gender groups.**

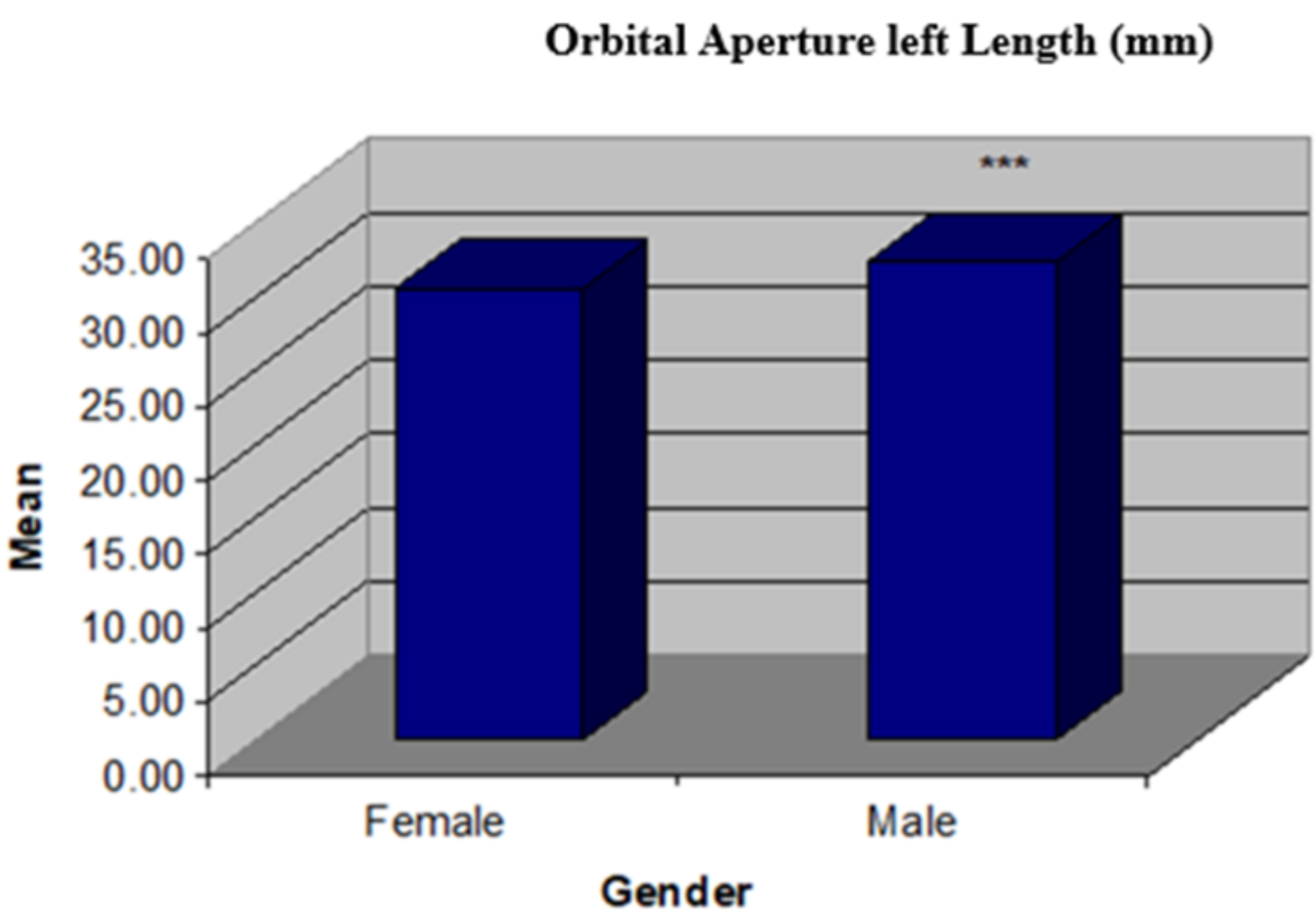


**Graph 7c . Comparison of difference in mean left orbital aperture length between two gender groups.**

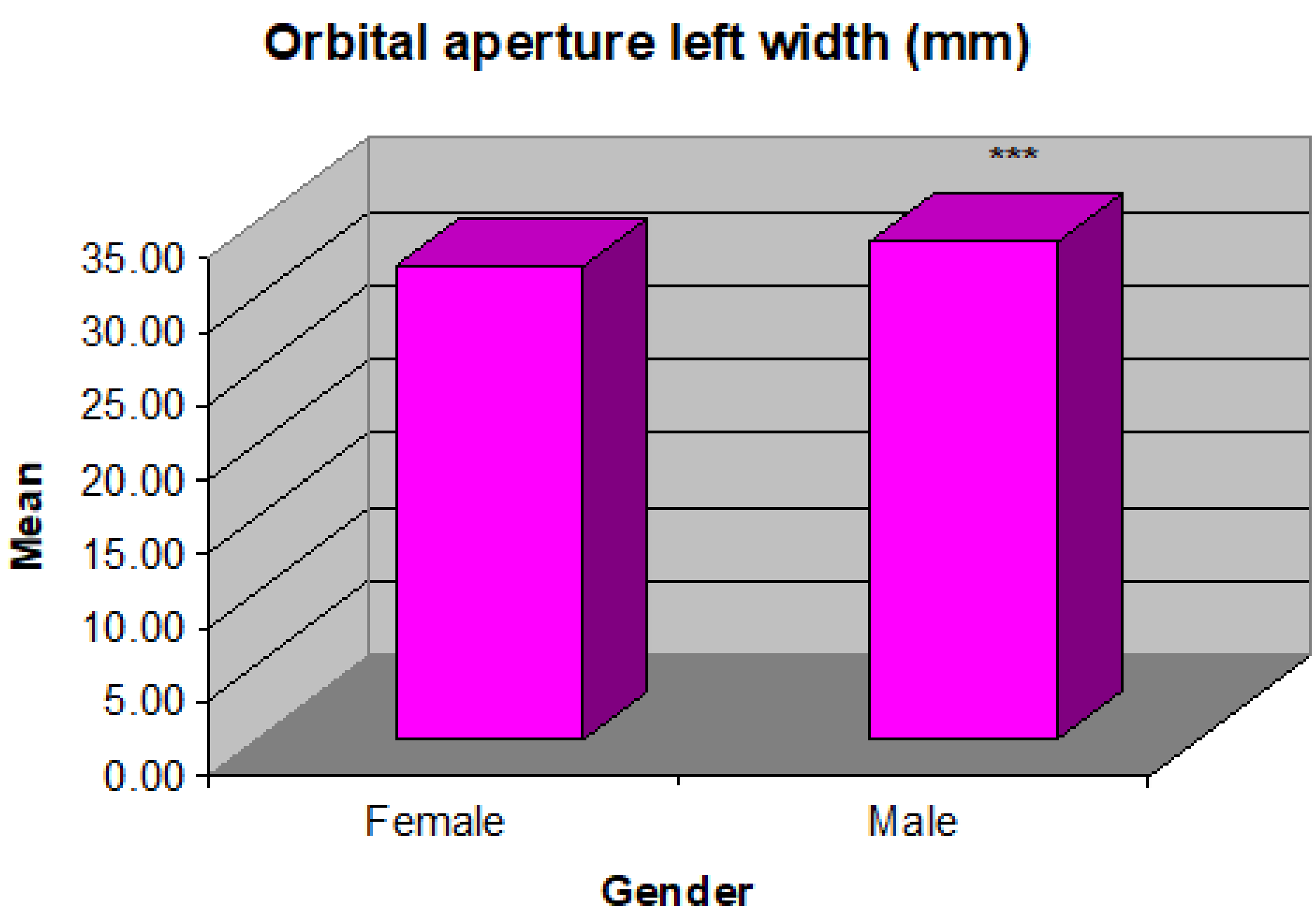


**Graph 7 d . Comparison of difference in mean left orbital aperture width between two gender groups**

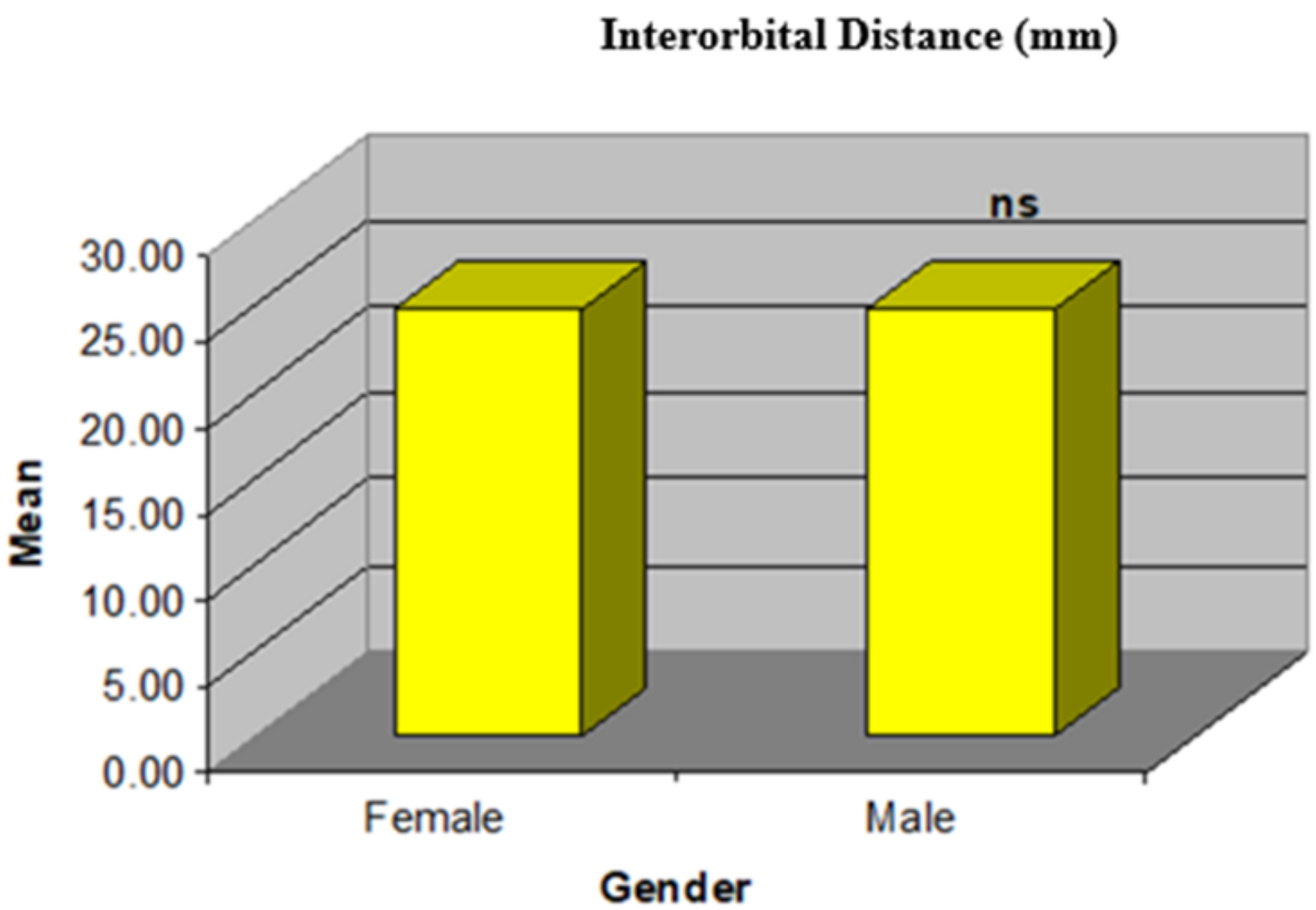


**Graph 7 e . Comparison of difference in mean orbital aperture interorbital distance between two gender groups.**

The observation in **table 7** shows comparison of the difference in mean orbital aperture between both genders. Right length **(Graph 7 a)** in males with mean deviation 33.74 ± 2.49 was higher than females with mean deviation 30.86 ± 3.34 was found significant ($p<.001$). right width **(graph 7 b)** in males with mean deviation 33.99 ± 2.24 was higher than females with mean deviation 32.62 ± 2.18 was found significant ($p<.001$). left length **(graph 7 c)** in males with mean deviation 32.40 ± 3.23 was higher than females with mean deviation 30.51 ± 3.35 was found significant ($p<.001$). left width (graph 7 d) in males with mean deviation 33.66 ± 2.34 was higher than females with mean deviation 32.10 ± 2.43 was found significant ($p<.001$). The mean interorbital distance **( graph 7 e)** did not differ ($P > 0.05$) between the two gender

**The mean width orbital aperture varied with gender and it was also comparatively higher in males as compared to females except interorbital distance.**

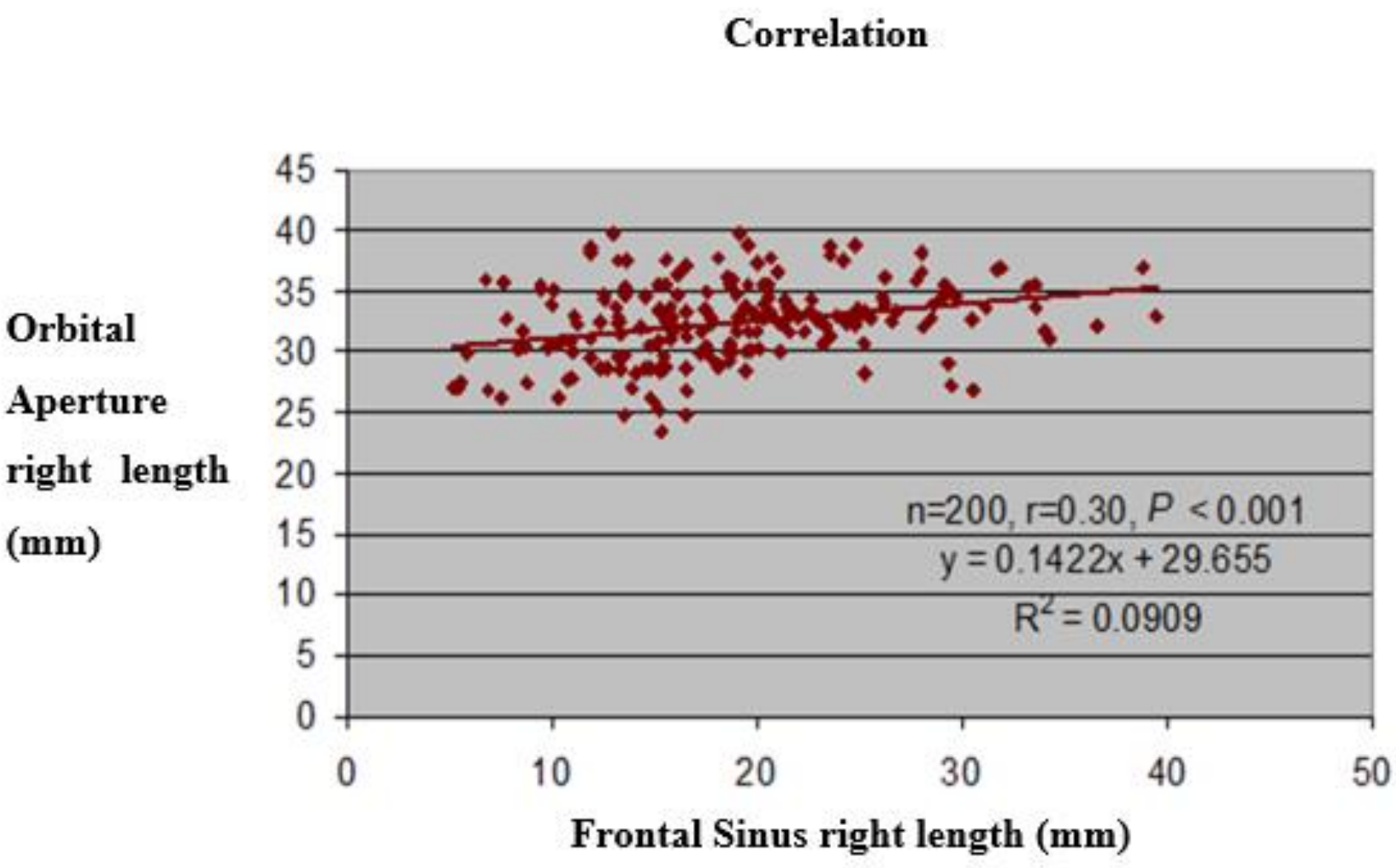


**Graph 8 . Correlation between frontal sinus right length and orbital aperture right length Correlation between frontal sinus right length and orbital aperture right length.**

Between frontal sinus and orbital aperture, significant ($P < 0.05$ or $P < 0.01$ or $P < 0.001$) and positive correlation was found between frontal sinus and orbital aperture variables (except frontal sinus right height and orbital aperture right height, frontal sinus right height and orbital aperture right width, and frontal sinus right height and orbital aperture left height) with highest being between frontal right length and orbital aperture right length ( $P < 0.001$) (Graph 8).

**Frontal sinus variables showed high correlation with each other than orbital aperture variables. Further, interorbital distance did not ($P > 0.05$) correlate well with both frontal sinus and orbital aperture.**

# DISCUSSION

Forensic dentistry a branch of dentistry dealing with the proper handling and examination of evidence and proper evaluation and presentation of dental findings

The word Forensic is derived from the Latin word forensis: public; to the forum or public discussion; argumentative, belonging to debate or discussion [1]

Dentomaxillofacial Radiography is quite common in dental clinics and hospitals and are utilized in identification. Metric analyses on the radiographs are of superior value due to their objectivity, accuracy, and reproducibility [2]

The skeleton survives both natural and unnatural abuse or violence and is available for human identification due to the dimorphic characteristics of the human skeleton. After pelvis skull is the second-best region for identification.

Skull is sexually dimorphic so it is helpful in human identification with an accuracy of 92%. Dentition, cranial suture patterns, vascular groove patterns, sella turcica area of sphenoid, frontal sinuses, mastoid pneumatic air cells and orbital apertures acts as an adjuvant for human identification. [57]

Cephalometry is cost- effective and well-established method for examining patients with dentofacial deformities. Posteroanterior (PA) cephalometric projections are an important adjunct for qualitative and quantitative evaluation of the dentofacial region. This radiograph is a valuable tool for comparing right and left structures as they are located at relatively equal distances from the film and radiographic source. PA cephalogram provides useful information concerning overall morphology, shape and size of the skull, bone density, suture morphology and deviations. Further, it can contribute to the detection of pathology of the hard and soft tissues [4]

The significance of frontal sinus in personal identification is emphasized by anatomists, radiologists, as well as anthropologists who have stated that no two frontal sinuses are alike. Studies have been done to utilize sinus radiography for the identification of remains as well as determination of sex and race. [24]

Frontal sinuses are pneumatic cavities which is radiologically evident at the age of five or six and is fully developed by the age of 20 years. Various studies have suggested that the frontal sinuses is greater in males than in females. Frontal sinuses are different in monozygotic and dizygotic twins and thus can be used for identification. Frontal sinus patterns have a potential aid for personal identification, age estimation and sexual dimorphism [12]

Human skulls have been used to measure the morphological variations of orbital and orbital bone which is used in forensic medicine as a parameter for sexual and ethnic determination in human identification.

The orbital aperture morphometry is a valuable tool in gender determination as the orbit possesses resistance to damage and disintegration processes.[2]

Only few researches have been done to assess the morphology of both frontal sinus and orbital aperture, hence the present study was conducted for age and gender determination through evaluation of morphology of frontal sinus and orbital aperture by using digital postero- anterior cephalograms.

The present study was conducted on 200 subjects who visited the department of Oral Medicine and Radiology, Babu Banarasi Das College of Dental Sciences, Lucknow. The patients were divided into two groups, Group A and Group B.

Group A- 100 males

Group B- 100 females

Both the groups were subjected for digital postero- anterior cephalometric radiographs and then measurement of frontal sinus and orbital aperture was done digitally.

1. **Age and Gender distribution of the subjects (Table 1)**

In the present study the subjects 100 males and 100 females were included with the age range of 15 – 70 years.

Study conducted by **Tiwari et al (2016) [53]** with 160 subjects (80 males and 80 females) with age range of 15- 55 years to determine the role of frontal sinus through the dimensions of frontal sinus by gender, side and age.
**Ghori et al (2017) [2]** conducted study on 50 males and 51 females in the age group between 20 and 50 years to evaluate the orbital aperture dimensions in individuals and verify their relationship with gender.

Another study conducted by **Shireen et al (2019) [59]** with 400 subjects (200 males and 200 females), aged 14–70 years for morphometric evaluation of the frontal sinus by using digital posteroanterior skull radiograph in relation to age and gender and its role in forensic

Studies conducted have shown frontal sinus develop fully by the age of 20 years and ceases after 20 years and become stable .[58]

2. **Frontal Sinus comparison and measurements among different age (Table 2 and 3)**

The present study shows that frontal sinus decrease in the right length ( graph 3 a) with mean difference 3.40 mm which was significant (P <0.05) in age group > 55years as compared to 15- 55 years; there was decrease in right width (graph 3 b) with mean difference 6.85 mm which was significant ( p<0.01) in age group > 55 years as compared to 15- 55 years; a decrease was seen in frontal sinus right area ( graph 3 c) with mean difference 136.40 mm in age group > 55 years as compared to 15- 55 years which was significant ( p <0 .001). Frontal sinus left width (graph 3 e) and left area (graph 3 f) also showed decrease in age group > 55 years as compared to 15- 55 years with mean differences of 8.25 and 141.75 mm respectively which was significant (p<0.001 and p<0.01). Frontal sinus left length (graph 3 d) showed no significant changes in age group (p >0.05) with mean difference 0.83 mm.

Similar study conducted by **Tiwari et al (2016)** **[53]** showed significant (p < 0.01) decrease the frontal sinus between 15-55 years for right height with mean difference 30.07 mm; right width with mean difference 28.93mm; right area with mean difference 911.25 mm and left height with mean difference 31.92mm. But no significant (p > 0.05) difference between different age groups for left frontal sinus width with mean difference 32.11mm and area 970.56 mm which was not in concordance with the present study which showed no significant changes in left length in different age group (p >0.05) with mean difference 0.83 mm.

The probable reason for the size of frontal sinus to decrease in size with increasing age is that the growth of frontal continues through puberty [60] and ceases at about 20 years of age, with stable shape and size of the sinus. [61]

**3. Orbital Aperture comparison and measurements among different age (Table 4 and 5).**

In the current study the right orbital aperture length (graph 5 a) in age group of 15- 55 years as compared to > 55 years with mean difference 0.53 mm showed no significant changes ( p > 0.05); right orbital aperture width ( graph 5 b) in age group of 15- 55 years as compared to > 55 years with mean difference 0.04 mm showed no significant changes (p>0.05) ; left orbital aperture length (graph 5 c) with mean difference 0.91 mm showed no significant changes ( p. 0.05); left orbital aperture width ( graph 5 d) in the age group 15- 55 years as compared to > 55 years also showed no significant changes ( p> 0.05); inter- orbital distance ( graph 5 e) in age group of 15- 55 years as compared to > 55 years showed no significant changes (p>0.05)

Study conducted by **Chen et al. (2002)** **[62]** showed dissimilar results. In their study 39 subjects were included to measure ocular and orbital parameter using head CT images. The study found the orbital width with standard deviation of 2.1 mm; orbital height with standard deviation of 2.3 mm which were significant (P < 0.05) or mildly significant (P < 0.10). the study concluded that the orbit widened and increased with increasing age.

Study conducted by **Mendelson et al. (2007)** **[39]** showed results in accordance with the present study. In their study 62 patients ranging in age from 21 to 70 years were included and facial CT scans were taken. Orbital superior length with mean deviation 0.16mm and inferior length with mean deviation 0.14 mm which was not significant were measured (p= 0.2) the study resulted in no significant changes in these distances with aging, indicating that the central portion of the superior and inferior orbital rims do not recede with aging.

In regards to aging of the bony orbit, there is enlargement in the bony orbit with changes to its curvilinear form with increasing age. The volume of the bony orbit has also been shown to increase with age and also the bone recedes with increasing age [36]

**4. Frontal sinus comparison and measurements among both the gender (Table 6)**

The present study shows that the right frontal sinus width (graph 6 b) in males with mean deviation 21.18 ± 6.67 was higher than in females with mean deviation 16.03 ± 6.24 was found significant ($p < 0.001$). Right area (graph 6 c) in males with mean deviation 275.67 ± 161.18 was higher than in females with mean deviation 201.39 ± 125.90 was found to be significant ($p <0.001$). left length (graph 6 d) in males with mean deviation 15.05 ± 5.65 was found to be higher than females with mean deviation 13.00 ± 4.26 was found to be significant ($p <0.01$). left width (graph 6 e) in males with mean deviation 23.53 ± 8.27 was found to be higher than females with mean deviation 17.67 ± 6.39 was found to be significant ($p <0.001$). left area (graph 6 f) in males with mean deviation 360.16 ± 208.69 was found to be higher than females with mean deviation 239.86 ± 136.82 was found to be significant ($p <0.001$). The mean frontal sinus right length (graph 6 a) was found to be not significant ($P > 0.05$), it was similar in both genders

Study conducted by **Belaldavar C et al., (2014) [26]** was in accordance. 300 digital postero-anterior view radiographs were obtained from 150 males and 150 females aged between 18-30 years showed significance ($p<0.05$) with mean values of the frontal sinus length (males- 1.47 cm and females 1.17 cm), width ( males- 2.64 cm and females 2.22 cm) and area (males- 3.58 $cm^2$ and females 2.33 $cm^2$ ) are greater in males.

Another study conducted by **Soman et al., (2016) [3]** which was similar to the present study, where 200 subjects (100 males and 100 females) in the age groups 14-55 years and above showed that frontal sinus length and width were greater in males than females.

**Denny C et al., (2018) [63]** conducted showed similar results. In their study 100 cone beam computed tomography (CBCT) images (50 males and 50 females) to measure the frontal sinus in coronal, sagittal, and axial planes. While comparing both genders, the measurements were greater in males which was statistically significant ($p < 0.005$) results were obtained on comparing between the sides and gender.

The gender differences in sizes of frontal sinus is due to genetic factors, even environmental factors as nutrition, as well as hormonal and muscular factors, play a role. [27]

## 5. Orbital aperture comparison and measurements among both the gender (Table 7)

The observation shows comparison of the difference in mean orbital aperture between both genders. Right length (graph 7 a) in males with mean deviation 33.74 ± 2.49 was higher than females with mean deviation 30.86 ± 3.34 was found significant (p<.001). right width (graph 7 b) in males with mean deviation 33.99 ± 2.24 was higher than females with mean deviation 32.62 ± 2.18 was found significant (p<.001). left length (graph 7 c) in males with mean deviation 32.40 ± 3.23 was higher than females with mean deviation 30.51 ± 3.35 was found significant (p<.001). left width (graph 7 d) in males with mean deviation 33.66 ± 2.34 was higher than females with mean deviation 32.10 ± 2.43 was found significant (p<.001). The mean interorbital distance (graph 7 e) did not differ (P > 0.05) between the two gender.

Study conducted by **Mahalakshmi M et al (2019)** **[56]** showed similar results that the mean orbital width in males was 4.91 and females was 4.97. The observed mean difference was statistically significant (P-0.005). The mean orbital length in males was 4.96 and females was 4.86. The observed mean difference was statistically significant (P-0.001). All the parameters were greater in males than females.

**Rossi et al. (2012)** **[37]** conducted a study which is in accordance with the present study. The study evaluated the dimensions of the orbital aperture to gender. Orbital breadth orbital length and inter orbital breadth were measured. Results revealed the significant difference for orbital breadth and inter-orbital breadth between sexes. The study reported that the breadth of orbital aperture is < 3.5 cm the skull is of female and if it is > 3.5 cm is of a male. If the inter-orbital distance is < 2.4 cm the skull is likely to be a female and if it is > 2.5 cm, it is likely to be a male.

Orbits show significant sexual dimorphism among parts of the skull, with male orbits being characteristically squarer and relatively larger, while female orbits are rounder and comparatively smaller. However, age, sex, ancestry, and evolutionary periods cause variation in the orbital characteristics [40]

## 6. Correlation of frontal sinus and orbital aperture. (Graph 27)

Correlation between frontal sinus and orbital aperture was made which was significant (P < 0.05 or P < 0.01 or P < 0.001) and positive correlation was found between frontal sinus and orbital aperture variables, with highest being between frontal right length and orbital aperture right length (P < 0.001).

The above results show that the frontal sinus size decreases with the increasing age. The orbital aperture showed no changes with increasing age. Among both the genders males have a larger frontal sinus than females. The orbital aperture is also greater in males than in females

# SUMMARY AND CONCLUSION

Personal identification is the establishment of the identity of an individual. The need arises in natural mass disasters and in man-made disasters and in cases when the body is highly decayed or dismembered and in and medico-legal purposes.

Two important parameters of this study are Orbits and Frontal sinus which are dimorphic, unique and can be an asset to forensic study.

The frontal sinuses are two in number and lies between the external and internal aspects of frontal bone. They are asymmetrical and lies at the medial part of the orbital roof. The significance of frontal sinus in forensic sex determination is due to their unique pattern. The frontal sinus is unique even in monozygotic twins. The outline of the frontal sinus is irregular, and the dimensions of the frontal sinus are convenient for being measured. The sinuses develop by the age of two years and grow slowly until puberty, until completing growth at approximately 20 years. Changes in the adult sinuses are rare and are generally stable throughout life hence can be assessed through linear and area measurements in adult male and female subjects. Studies conducted to determine the forensic importance of frontal sinus radiographs in determination of gender.

Human skulls are been used to measure morphological variations of the orbital aperture and orbital bone and can be used as a parameter for sexual and ethnic determination in human identification. The orbital aperture morphometry is an important asset in gender determination since orbit is resistance to damage and disintegration processes.

Only few researches have been done to assess the morphology of both frontal sinus and orbital aperture, hence the need was felt to conduct a study for age and gender determination through evaluation of morphology of frontal sinus and orbital aperture.

So, the present study was designed with the aim to assess frontal sinus and orbital aperture for the use in forensic dentistry using postero- anterior cephalograms in Department of Oral Medicine and Radiology, Babu Banarasi Das College of Dental Sciences, Lucknow.

In the present study the subjects were divided into two groups, Group A and Group B. Group A- 100 males; Group B – 100 females.

- In the present study the frontal sinus right and left length, width, area was found to be decreasing with age which was statistically significant
- The orbital aperture right and left length and width as well as the inter- orbital distance remains same with changes in all age groups
- Results of the present study also revealed the frontal sinus right and left height, width and area was found to be greater in males than females which was statistically significant.

- The orbital aperture right and left height and width was found to be more in males than in females except for inter- orbital distance.
- The present study correlation was made between the frontal sinus and orbital aperture which was significant ($P < 0.05$ or $P < 0.01$ or $P < 0.001$) and positive correlation was found between frontal sinus and orbital aperture variables with highest being between frontal right height and orbital aperture right height ($r=0.30$, $P < 0.001$).
- Importantly, frontal sinus variables showed high correlation with each other than orbital aperture variables. Further, interorbital distance did not ($P > 0.05$) correlate well with both frontal sinus and orbital aperture.

Both Frontal sinus and Orbital aperture can be used to assess the age and gender in forensic dentistry since these structures possesses resistance in damage and can be used in human identification. These anatomical structures have importance in mass disasters victim identifications and in medico-legal aspects.

Thus, further study with larger population have scope for validation of the present study.

# REFERENCES


1. P. Ratnakar, G.S.Singaraju. Methods of identification in forensic Dentistry. Annals and Essences of Dentistry 2010 Jan-Mar;2(1):26-8.
2. Ghorai Laboni, Asha M.L., Lekshmy J., Rajarathnam Neelakantam Basetty, Kumar Mahesh H.M. Orbital aperture morphology in Indian population: A digital radiographic study. J Forensic Dent Sci. 2017 May-Aug;9(2):61-4.
3. Soman A. Bhakti, Sujatha G.P., Lingappa Ashok. Morphometric evaluation of frontal sinus in relation to age and gender in subjects residing in Davangere, Karnataka. J Forensic Dent Sci.2016 Jan-Apr;8(1):57
4. Bajaj Kamal, Rathee Pooja, Jain Pradeep, Panwar Raja Vasim. Comparison of the Reliability of Anatomic landmarks based in PA Cephalometric Radiographs and 3D CT scans in patients with Facial Asymmetry. Int. J Clinical Pediatric Dentistry Sep-Dec 2011;4(3):213-23.
5. Kanchan Tanuj, Krishan Kewal. Personal dentification in Forensic Examinations. Anthropol 2013;2(1).
6. Verma Saumya, V.G. Mahima, Patil Karthikeya. Radiomorphometric analysis of frontal sinus for sex determination. J Forensic Dent Sci 2014 Sept-Dec;6(3).
7. Soman B. Frontal Sinus and Nasal Septum Together in Forensics: Strengthening the Evidence for Personal Identification. Austin J Forensic Sci Criminol 2017;4(4):1071.
8. Arora et al., Role of forensic odontology in the Indian Armed Forces: An unexplored arena. J Forensic Dent Sci. 2016 Sep-Dec; 8(3): 173.
9. Rai B et al., Criteria for determination of sex from mandible. The internal journal of science. 2007; 4(2).
10. Verma Kavita et al., Use of Frontal Sinus and Nasal Septum as an Aid in Personal Identification and Determination of Gender: A Radiographic Study. Journal of Clinical and Diagnostic Research 2017; 11(1).
11. Sinha S, Umapathy D, Shashikant MC, Misra N, Mehra A, Singh AK. Dental age estimation by Demirjian' sand Noll's method: A comparative study among children attending a dental college in Lucknow (UP). J Indian Acad Oral Med Radiol 2014; 26:279-86
12. David Priscilla et al., use of frontal sinus and nasal septum patterns as an aid in personal identification: A digital radiographic pilot study. J Forensic Dent Sci. 2010; 2(2): 77-80
13. Botwe et al., Radiological evaluation of orbital index among Ghanaians using CT scan. Journal of Physiological Anthropology. 2017;36:29.

14. N. Balachander et al., Evolution of forensic odontology: An overview. J Pharm Bioallied Sci. 2015; 7: 176–180.

15. Gopal Ji Misra, C. Damodaran. Perspective Plan for Indian Forensics. July 2010; 6-7.

16. Karandeep Singh Arora and Prabhpreet Kaur. Role of forensic odontology in the Indian Armed Forces: An unexplored arena. J Forensic Dent Sci. 2016 Sep-Dec; 8(3): 173.

17. J. Taylor. A Brief History Of Forensic Odontology And Disaster Victim Identification Practices In Australia. The Journal of forensic odonto-stomatology ·December 2009.

18. Robert Michael Bruce-Chwatt. A brief history of Forensic odontology since 1775. Journal of Forensic and Legal Medicine 17 (2010) 127–130.

19. Gurjot Kaur, Shivangi Chanana. Forensic Odontology and Its Indian Perspectives. JPAFMAT 2009; 9(1). ISSN 0972-5687.

20. Alla et al., Anatomical Variation of the Frontal Sinuses in Sudanese Children. International Journal of Research Studies in Medical and Health Sciences. 2017: 12(2); 22-27

21. Surgical Anatomy of the Paranasal Sinus- M. Pais Clemente

22. Moore et al., Frontal Sinus Development and Juvenile Age Estimation. Ant Rec. 2017:300;(1609-17)

23. B.D. Chaurasia's Human Anatomy 6th edition, Volume 3, Pages- 245-247

24. Garhia et.al. Frontal sinus: A tool in forensic identification. Int J Cur Res Rev.2019;11(8)

25. Kumar, et al.: Frontal sinus as a tool in identification. Int J Forensic Odontol 2018;3:55-8.

26. C Belaldavar et al., Assessment of frontal sinus dimensions to determine sexual dimorphism among Indian adults, J. Forensic Dent. Sci. 6 (1) (2014) 25–30.

27. Gopal KS et al., Significance of Frontal sinus and Nasal Septum Patterns in Personal Identification in Forensics. A retrospective CBCT Study. Int J Oral Health Med Res. 2016;2:57-61

28. Verma P et al., combined use of frontal sinus and nasal septum patterns as an aid in forensics: A digital radiographic study. North Am J Med Sci. 2015;7:47

29. Kanjani V et al., Morphometric analysis of the orbital aperture in North Indian Population: A retrospective digital forensic study. Int J App Basic Med Res 2019;9:85-8.

30. Caleb L et al., Anatomy, Head and Neck, Orbit Bones - StatPearls - NCBI Bookshelf

31. Hatem et al., Embryologic and Fetal Development of the Human Orbit. (Ophthal Plast Reconstr Surg 2018;34:405–421

32. Tomasik et al., Development of human eyeball and orbit during fetal life. Annals of Pomernian Medical University. 2005;51: 37-40

33. C Rene et al., Update on orbital anatomy. Eye .2006;20 (1119–29).

34. Martins et al., Microsurgical Anatomy of the Orbit: The Rule of Seven. Hindawi Publishing Corporation Anatomy Research International. 2011

35. Murat et al., Evaluation of Eyeball and Orbit in Relation to Gender and Age. The Journal of Craniofacial Surgery. 2016; 27( 8)

36. Kahn David et al., Aging of the Bony Orbit: A Three-Dimensional Computed Tomographic Study. Aesthetic Surg J 2008; 28:258-64)

37. Rossi et al., Orbital aperture morphometry in Brazilian population by postero-anterior Caldwell radiographs. J Forensic Leg Med.2012;19: 470-3.

38. Wong et al., Changes in the Facial Skeleton With Aging: Implications and Clinical Applications in Facial Rejuvenation. Aesth Plast Surg (2012) 36:753–760

39. Mendelson et al., Age-Related Changes of the Orbit and Midcheek and the Implications for Facial Rejuvenation. Aesth. Plast. Surg. 2007;30:1(6)

40. Ashley et al., CT Based Three-Dimensional Measurement of Orbit and Eye Anthropometry. Investigative Ophthalmology & Visual Science. 2015; 51: 10

41. Manigandan T. et al., Forensic radiology in dentistry. 2015 J Pharm Bioallied Sci. 2015; 7(1): 260–64

42. Swan LK et al., Estimating eyeball protusion from body height, interpupillary distance and inter orbital distance in adults. J Forensic Sci.2005;50:774-6

43. Bullen Rubira et al., Frontal Sinus size on facial plain radiographs. J. Morphol. Sci.2010;27(2):77-81

44. Damstra Janalt et al., Evaluation and comparison of postero-anterior cephalograms and cone beam computed tomography images for detection of mandibular asymmetry. European Journal of Orthodontics.2013; 35(1):45-50

45. Eric Whaites 3rd edition. Skull and maxillofacial radiology. Essentials of Dental Radiography and Radiology.

46. Oral Radiology Principles and Interpretations. White and Pharoah. 6th edition

47. Malkoc Sıddık et al., The effect of head rotation on cephalometric radiographs. European Journal of Orthodontics 2005; 27:315–321

48. Shokri A, Miresmaeili A et al., Effect of changing the head position on accuracy of transverse measurements of the maxillofacial region made on cone beam computed tomography and conventional posterior anterior cephalograms. Dentomaxillofac Radiol 2017; 46: 20160180.

49. Celik E, Polat- Ozsoy O and Memikoglu. Comparision of Cephalometric measurements with digital versus conventional cephalometric: A Comparision of conventional cephalometric analysis. European Journal of Orthodontics. 2009; 31: 241-46

50. Sangroula Pradip, Sardana Harish Kumar et al., Comparison of Reliability and Validity of Posteroanterior Cephalometric Measurements Obtained from AutoCEPH© and Dolphin® Cephalometric Software Programs with Manual Tracing. J Indian Orthod Soc 2018;52:106-14.

51. Paixão Bastos Mariane et al., Comparative study between manual and digital cephalometric tracing using Dolphin Imaging software with lateral radiographs. Dental Press J Orthod 2010;15(6):123-30

52. Mahto RK, Kharbanda OP, Duggal R, Harish HK. A comparison of cephalometric measurements obtained from two computerized cephalometric softwares with manual tracing. Journal of orthodontic socirty.2016;50(3).

53. Tiwari et al., Frontal Sinus- A Useful Personal Identification Tool. Journal of Oral Medicine, Oral Surgery, Oral Pathology and Oral Radiology.2016;2(1): 11-22

54. Gadekar NB et al. Forensic application of frontal sinus measurement among the Indian population. J Oral Maxillofac Pathol .2019;23:147-51

55. Kanjani V et al., Morphometric analysis of the orbital aperture in North Indian Population: A A retrospective digital forensic study. Int J App Basic Med Res 2019;9:85-8 56.

56. Mahalakshmi M, A. P Indira, Maria Priscilla David. Radiomorphometric evaluation of orbit and interorbital distance for gender determination. International Journal of Contemporary Medical Research 2019;6(4):13-15retrospective digital forensic study. Int J App Basic Med Res 2019;9:85-8.

57. Kumar AP, Doggalli N, Patil K. Frontal sinus as a tool in identification. Int J Forensic Odontol 2018;3:55-8

58. Phrabhakaran Nambiar et al., Anatomical Variability of the Frontal Sinuses and their Application in Forensic Identification. Clin. Anat. 12:16-19,1999

59. Shireen A, Goel S. Radiomorphometric evaluation of the frontal sinus in relation to age and gender in Saudi population. J Int Soc Prevent Communit Dent 2019;9:584-96

60. Verma P, Verma KG, Khosa R, Kumar S, Basavaraju S, Patwardhan N. Combined use of frontal sinus and nasal septum patterns as an aid in forensics: A digital radiographic study. North Am J Med Sci. 2015; 7:47.

61. Tabor Z, Karpisz D, Wojnar L, Kowalski P. An automatic recognition of the frontal sinus in x-ray images of skull. IEEE Trans Biomed Eng 2009;56:361–368.

62. Pessa JE Chen Y . Curve analysis of the aging orbital aperture. Plast Reconstr Surg. 2002;109:751–755; 756–760

63. Denny C, Jacob AS et al. Frontal Sinus as an aid in Gender Identification in Forensic Dentistry: A Retrospective Study using Cone Beam Computed Tomography. World J Dent 2018;9(1):34-37.

# ANNEXURE 1

## DISSERTATION PROFORMA

## RADIOMORPHOMETRIC ANALYSIS OF FRONTAL SINUS AND ORBITAL APERTURE FOR AGE AND GENDER DETERMINATION

DEPARTMENT OF ORAL MEDICINE & RADIOLOGY

Babu Banarasi Das College of Dental Sciences, Lucknow (U.P.)

---

OPD NO: Case No:

Name: Age: Sex:

Martial status: Occupation:

Address:

Contact No:

Chief Complaint:

History of present illness:

Past Medical History:

Dental History:

Drug History and Allergy:

Family History:

Personal History:

Oral Hygiene Habits:

Abusive Habits:

## GENERAL PHYSICAL EXAMINATION:

Built: Gait:

Nourishment: Palor:

Mental state: Cynosis:

Icterus: Clubbing:

## Vital Sign:

Blood Pressure: Temperature:

Pulse: Respiratory rate:

## EXTRAORAL EXAMINATION:

Mouth Opening:

Facial Symmetry:

Lymph Node:

Temporomandibular Joint:

## INTRAORAL EXAMINATION (Hard Tissue Examination):

Teeth Present:

Missing:

Dental Caries:

Tenderness on percussion:

Attrition, Abrasion, Erosion:

Mobility:

Color, Size, Shape:

Occlusion:

Others:

## SOFT TISSUE EXAMINATION:

Lips: -

Labial mucosa: -

Buccal mucosa: -

Vestibule: -

Tongue: -

Floor of mouth: -

Hard & Soft palate:-

## Gingival & Periodontal Status:

Colour: -

Contour: -

Consistency: -

Surface texture: -

Recession: -

Bleeding on probing: -

Pocket: -

## OTHER FINDINGS:-

Stains: -

Calculus: -

## Provisional Diagnosis:

## Radiographic Investigations (POSTERO-ANTERIOR CEPHALOGRAM):

## FRONTAL SINUS

| Left | Right |
|---|---|
| Length: | length: |

Width: Width:

**ORBITAL APERTURE**

Left Right

Length: Length:

Width: Width:

Interorbital distance:

STUDENT SIGNATURE GUIDE SIGNATURE

# ANNEXURE 2

## CONSENT FORM

Title of the study…………………………….

Study Number……………………………….

Subject's Full Name…………………………

Date of Birth/Age…………………………….

Address of the Subject……………………….

Phone No. and email address………………...

Qualification…………………………………

Occupation: Student/ Self employed / Service/Housewife/Other

1. I confirm that I have read and understood the Participant Information Document dated ……………. for the above study and have had the opportunity to ask questions

   OR

   I have been explained the nature of the study by the investigator and had the opportunity to ask questions.
2. I understand that my participation in the study is voluntary and given with the free will without any duress and that I am free to withdraw at any time, without given any reason and without my medical care or legal rights being affected.
3. I understand that the sponser of the project, others working on the sponsor's behalf, the Ethics Committee and the regulatory authorities will not need my permission to look at my health records both in respect of the current study and any further research that may be conducted in relation to it, even if I withdraw from the trail. However, I understand that my identity will not be revealed in any information released to third parties or published.
4. I agree not to restrict the use any data or results that arise from this study provided such a use is only for scientific purpose(s).
5. I agree to participate in the above study for the future research

   Yes [ ]  No [ ]  Not Applicable [ ]
6. I have been explained about the study, and have fully understood them. I have also read and understand the participant/volunteer's information document given to me.

Signature/Thumb impression of the subject/Legally acceptable

Representative……………………………………………………….

Signatory's Name………………………………..Date……......

Signature of Investigator's Name………………………………

Study Investigator's Name……………………….Date………..

Signature of the witness…………………………………………

Name of witness…………………………………..Date………..

Received a signed copy of the duly filled consent form

Signature/Thump Impression of the subject/Legally acceptable

representative……………………………………….Date………

## <u>सहमति पत्र</u>

अध्ययन का शीर्षक.....................................................................................
अध्ययन संख्या.........................................................................................
विषय का पूरा नाम....................................................................................
जन्म / आयु की तिथि.................................................................................
विषय का पता
फोन नंबर और ईमेल पता..........................................................................
योग्यता...................................................................................................
व्यवसाय: छात्र / स्वयं नियोजित / सेवा / गृहिणी / अन्य

1. मैं पुष्टि करता हूं कि मैंने प्रतिभागी सूचना दस्तावेज को पढ़ और समझ लिया है ..................उपर्युक्त अध्ययन के लिए और प्रश्न पूछने का अवसर मिला है

या

मुझे जांचकर्ता द्वारा अध्ययन की प्रकृति की व्याख्या की गई है और मुझे प्रश्न पूछने का अवसर मिला है।

2. मैं समझता हूं कि अध्ययन में मेरी भागीदारी स्वैच्छिक है और किसी भी दुविधा के बिना मुफ्त इच्छा के साथ दी गई है और मैं किसी भी समय बिना किसी कारण के और.................................................................................... बिना चिकित्सा देखभाल या कानूनी अधिकारों के प्रभावित किए बिना वापस लेने के लिए स्वतंत्र हूं।

3. मैं समझता हूं कि परियोजना के प्रायोजक, की तरफ से काम करने वाले अन्य लोग, नैतिकता समिति और नियामक प्राधिकरणों को वर्तमान अध्ययन के संबंध में और मेरे आगे के किसी भी शोध के संबंध में मेरे स्वास्थ्य रिकॉर्ड देखने की अनुमति की आवश्यकता नहीं होगी इसके संबंध

में आयोजित किया गया, भले ही मैं निशान से पीछे हट जाऊं। हालांकि, मैं समझता हूं कि मेरी पहचान तीसरे पक्ष को जारी या प्रकाशित किसी भी जानकारी में प्रकट नहीं होगी।

4. मैं इस अध्ययन से उत्पन्न होने वाले किसी भी डेटा या परिणामों के उपयोग को प्रतिबंधित नहीं करने के लिए सहमत हूं बशर्ते ऐसा उपयोग केवल वैज्ञानिक उद्देश्यों के लिए है।

5. मैं भविष्य के शोध के लिए उपर्युक्त अध्ययन में भाग लेने के लिए सहमत हू

हां ☐ नहीं ☐ लागू नहीं ☐

6. मुझे अध्ययन के बारे में समझाया गया है, और उन्हें पूरी तरह से समझ लिया है। मैंने मुझे दिए गए प्रतिभागी / स्वयंसेवक के सूचना दस्तावेज को भी पढ़ और समझ लिया है।

विषय / कानूनी रूप से स्वीकार्य के हस्ताक्षर / अंगूठे की छाप

प्रतिनिधि.........................................................................

हस्ताक्षरकर्ता का नाम........................................................

जांचकर्ता के नाम का हस्ताक्षर..........................................

अध्ययन जांचकर्ता का नाम ........................... ... दिनांक.................

गवाह का हस्ताक्षर............................................................

गवाह का नाम ................................................... दिनांक .................

विधिवत भरे सहमति फॉर्म की एक हस्ताक्षरित प्रति प्राप्त की

विषय / कानूनी रूप से स्वीकार्य प्रतिनिधि के हस्ताक्षर / थंप इंप्रेशन ........................................................................ दिनांक .................

## ANNEXURE 3

## Child consent Form

Study Number ____________________________________________

Subject's Full Name _________________________________________

Date of Birth/Age__________________________________________________

Address____________________________________________________________________
__________________________________________________

I ____________________________________________ exercising my free power of choice, hereby give my consent for participating in the study entitled:

I have been informed, to my satisfaction, by the attending physician, about the purpose of the study and the nature of the procedure to be done. I am aware that my parents/guardians do not have to bear the expenses if the treatment if I suffer from any procedure related injury, which has casual relationship with the said study. I am also aware of right to opt out of the study, at any time during the course of the study, without having to give reasons for doing so

Signature if the study participant ______________________ Date:______

Name of the study participant ________________________

Signature of the Witness___________________________ Date:______

Name of the Witness_____________________

Signature of the attending Physician_____________________ Date:________

Name of the attending Physician_____________________

## शिशु सहमति पत्र

मै ____________________________________________________________ मे भाग लेने के लिए अपनी सहमती प्रदान करता हूँ। मुझे इस अध्ययन के हेतु और उसमे की जाने वाली प्रक्रिया के बारे मे चिकित्सक द्वारा बता दिया गया है। मुझे पता है कि अध्ययन सम्बन्धि किसी हानि जिसका अध्ययन की दवा से सम्बन्ध है उसका खर्च मेरे माता पिता अथवा अभिभावक को नही करना है। मुझे यह भी पता है कि मै इस अध्ययन से किसी समय बिना कोई कारण बताए बाहर हो सकता हूँ।

अध्ययन मे भाग लेने वाले का नाम और हस्ताक्षर

______________________________________________________________________

दिनांक ________________________गवाह के हस्ताक्षर

________________________________ दिनांक _________________________

गवाह का नाम ______________________________________

चिकित्सक का नाम और हस्ताक्षर

____________________________________________________

दिनांक_________________________

# ANNEXURE 4

**BABU BANARASI DAS COLLEGE OF DENTAL SCIENCES**
**(FACULTY OF BBD UNIVERSITY), LUCKNOW**

## INSTITUTIONAL RESEARCH COMMITTEE APPROVAL

The project titled **"Radiographic Evaluation of Frontal Sinus and Orbital Aperture for Age and Gender Determination Among Lucknow Population."** submitted by **Dr Akansha Mishra** Post graduate student from the **Department of Oral Medicine & Radiology** as part of MDS Curriculum for the academic year 2018-2021 with the accompanying proforma was reviewed by the Institutional Research Committee present on **27th November 2018** at BBDCODS.

The Committee has granted approval on the scientific content of the project. The proposal may now be reviewed by the Institutional Ethics Committee for granting ethical approval.

**Prof. Vandana A Pant**
Co-Chairperson

**Prof. B. Rajkumar**
Chairperson

**ANNEXURE 5**

# Babu Banarasi Das University
## Babu Banarasi Das College of Dental Sciences,
## BBD City, Faizabad Road, Lucknow – 226028 (INDIA)

**Dr. Lakshmi Bala**
Professor and Head Biochemistry and
Member-Secretary, Institutional Ethics Committee

**Communication of the Decision of the VII$^{th}$ Institutional Ethics Sub-Committee**

**IEC Code: 11** **BBDCODS/01/2019**

**Title of the Project:** Radiographic Evaluation of Frontal Sinus and Orbital Aperture for Age and Gender Determination Among Lucknow Population.

**Principal Investigator:** Dr. Akansha Mishra **Department:** Oral Medicine & Radiology

**Name and Address of the Institution:** BBD College of Dental Sciences Lucknow.

**Type of Submission:** New, MDS Project Protocol

Dear Dr. Akansha Mishra,

The Institutional Ethics Sub-Committee meeting comprising following four members was held on 10$^{th}$ January 2019.

| | | |
|---|---|---|
| 1. | Dr. Lakshmi Bala<br>Member Secretary | Prof. and Head, Department of Biochemistry, BBDCODS, Lucknow |
| 2. | Dr. Amrit Tandan<br>Member | Prof. & Head, Department of Prosthodontics and Crown & Bridge, BBDCODS, Lucknow |
| 3. | Dr. Rana Pratap Maurya<br>Member | Reader, Department of Orthodontics & Dentofacial Orthopedics, BBDCODS, Lucknow |
| 4. | Dr. Sumalatha M.N.<br>Member | Reader, Department of Oral Medicine & Radiology, BBDCODS, Lucknow |

The committee reviewed and discussed your submitted documents of the current MDS Project Protocol in the meeting.
The comments were communicated to PI thereafter it was revised.

**Decisions: The committee approved the above protocol from ethics point of view.**

Forwarded by:

Lakshmi Bala 22/01/19

(Dr. Lakshmi Bala)
Member-Secretary
IEC

Member-Secretary
Institutional Ethic Committee
Babu Banarasi Das College of Dental Sciences
BBD University
Faizabad Road, Lucknow-226028

(Dr. B. Rajkumar)
Principal
BBDCODS

PRINCIPAL
Babu Banarasi Das College of Dental Sciences
(Babu Banarasi Das University)
BBD City, Faizabad Road, Lucknow-226028

# ANNEXURE 6

| SNO | OPD NO | NAME | Age (yrs) | Gende r | FRONTAL SINUS (RIGHT SIDE) | | | FRONTAL SINUS (LEFT SIDE) | | | ORBITAL APERTURE (RIGHT SIDE) | | ORBITAL APERTURE (LEFT SIDE) | | Interorbi tal distance (mm) |
|---|---|---|---|---|---|---|---|---|---|---|---|---|---|---|---|
| | | | | | Lenght (mm) | Width (mm) | Area (mm²) | Length (mm) | Width (mm) | Area (mm²) | Length (mm) | Width (mm) | Length (mm) | Width (mm) | |
| 1 | 16280 | Jyoti Sharma | 18 | F | 25.2 | 26.2 | 660.24 | 16.5 | 24.9 | 410.85 | 34 | 33.9 | 32 | 34 | 24.9 |
| 2 | 83845 | Naryani Singh | 21 | F | 13.3 | 13.2 | 175.56 | 13.9 | 11 | 152.9 | 32.2 | 33.9 | 34.2 | 33.5 | 20.7 |
| 3 | 4650 | Atul Kumar | 16 | M | 9 | 23.2 | 208.8 | 10.4 | 30.4 | 316.16 | 30.6 | 32.2 | 28.8 | 33 | 22.9 |
| 4 | 76020 | Aayush | 24 | M | 11.6 | 33.6 | 389.76 | 11.7 | 32 | 374.4 | 35.5 | 34.8 | 30.3 | 34 | 22.2 |
| 5 | 80760 | Dharam Raj | 25 | M | 11.3 | 20.3 | 229.39 | 11.9 | 19.4 | 230.86 | 35.5 | 31.3 | 31 | 28.7 | 21.4 |
| 6 | 75220 | Harmeet | 25 | F | 13.3 | 15.2 | 202.16 | 16.8 | 13.3 | 223.44 | 28.4 | 34.2 | 27.8 | 33.3 | 23.2 |
| 7 | 70760 | Ritika | 24 | F | 19.4 | 14.3 | 277.42 | 11.3 | 12 | 135.6 | 32 | 34.3 | 30.6 | 31.7 | 21.3 |
| 8 | 6758 | Anjum Yadav | 16 | F | 19.4 | 13.2 | 256.08 | 16.1 | 13.9 | 223.79 | 29.7 | 34.6 | 33.9 | 32 | 21.3 |
| 9 | 14315 | Priyal Gupta | 20 | F | 13.6 | 15.9 | 126.24 | 12.3 | 17.1 | 217.71 | 32 | 34.9 | 31.7 | 31.3 | 27.5 |
| 10 | 58225 | Golo Pandey | 20 | M | 13.6 | 29.7 | 403.92 | 13 | 39.7 | 516.1 | 34.6 | 29.3 | 31.7 | 33.9 | 25.5 |
| 11 | 16980 | Abhishek | 29 | M | 25.8 | 36.5 | 941.7 | 23.8 | 40 | 952 | 32 | 34.6 | 28 | 37 | 27.1 |
| 12 | 66050 | Sachin Kumar | 26 | M | 16.1 | 33.2 | 534.52 | 21 | 34.5 | 724.5 | 35.3 | 39.4 | 34.2 | 36.1 | 25.5 |
| 13 | 2435 | Shivanshi | 23 | F | 15.5 | 15.2 | 235.6 | 20.3 | 17.8 | 361.34 | 33.5 | 29.5 | 30 | 30 | 20.9 |
| 14 | 2906 | Sabreen Banu | 30 | F | 6.8 | 10.3 | 70.04 | 9.1 | 11.3 | 102.83 | 26.2 | 32.4 | 25.9 | 31.7 | 20.3 |

| | | | | | | | | | | | | | | | |
|---|---|---|---|---|---|---|---|---|---|---|---|---|---|---|---|
| 15 | 65880 | Sira Rashid | 27 | F | 15.6 | 17.8 | 277.68 | 21.3 | 16.1 | 342.93 | 32.3 | 33 | 31.7 | 33.2 | 24.8 |
| 16 | 65800 | Surya Prakash | 28 | M | 15.2 | 34.2 | 519.84 | 26.8 | 30.4 | 814.72 | 31.1 | 33.9 | 27.8 | 31.7 | 22.7 |
| 17 | 57320 | Rajendra | 33 | M | 11.3 | 34 | 384.2 | 20.7 | 36.6 | 757.62 | 31.7 | 34.5 | 30.4 | 34.8 | 25.5 |
| 18 | 17565 | Vinay Prakash | 33 | M | 8.5 | 21.6 | 183.6 | 14.3 | 27.8 | 397.54 | 33.5 | 31.7 | 33.5 | 36.8 | 22.3 |
| 19 | 60365 | Kanchan | 34 | F | 11 | 11 | 121 | 14.6 | 14.8 | 216.08 | 30 | 33.3 | 30.7 | 28.7 | 20.7 |
| 20 | 51725 | Seema Verma | 32 | F | 10.6 | 13.3 | 140.98 | 10.6 | 13.2 | 140.98 | 31.5 | 36.8 | 31.7 | 35.9 | 20.7 |
| 21 | 1080 | Eram | 36 | F | 13.9 | 11.9 | 165.41 | 8.8 | 9.7 | 85.36 | 38.5 | 34 | 36.5 | 36.2 | 27.5 |
| 22 | 4250 | Savita Singh | 38 | F | 15.2 | 28.4 | 431.68 | 14.8 | 32.4 | 479.52 | 32.6 | 33.6 | 33.3 | 34.9 | 24.5 |
| 23 | 17750 | Sharmawati | 42 | F | 10.3 | 19.4 | 199.82 | 11 | 25.5 | 280.5 | 30 | 27.5 | 29.7 | 27.2 | 19.6 |
| 24 | 42615 | Vimla Kasyap | 43 | F | 10.3 | 14.5 | 149.35 | 12.6 | 22 | 277.2 | 28.7 | 31.7 | 27.1 | 33.3 | 26.8 |
| 25 | 3380 | Ganesh | 40 | M | 12.3 | 20 | 246 | 14.6 | 24.2 | 353.32 | 31.7 | 35.5 | 31.7 | 30 | 23.6 |
| 26 | 4565 | Rajendra | 36 | M | 9.3 | 20.3 | 188.79 | 8.1 | 26.5 | 214.65 | 34 | 34.9 | 32.6 | 33 | 22.2 |
| 27 | 9595 | Ram Sumer | 40 | M | 10 | 17.4 | 174 | 11 | 21.7 | 238.7 | 33.5 | 32.4 | 32 | 32.7 | 22.9 |
| 28 | 67200 | Santosh | 36 | M | 8.4 | 23.3 | 195.72 | 21.4 | 9 | 192.6 | 32 | 37.5 | 36.6 | 34.8 | 18.7 |
| 29 | 4825 | Dhaniram | 45 | M | 12.6 | 25.2 | 317.52 | 19 | 30 | 570 | 33.3 | 35.5 | 35.6 | 34 | 26.8 |
| 30 | 380 | Mukesh | 41 | M | 8.6 | 18.8 | 161.68 | 9.9 | 23.3 | 230.67 | 35.9 | 36.5 | 36.9 | 36.8 | 26.5 |
| 31 | 745 | Suraj | 42 | M | 11 | 23.6 | 259.6 | 11.7 | 25.3 | 296.01 | 37.9 | 37.7 | 30.1 | 32.9 | 23.6 |
| 32 | 4895 | Najuk | 46 | F | 13.2 | 16.5 | 217.8 | 10 | 24.9 | 249 | 37.2 | 34.2 | 29.4 | 36.2 | 25.2 |
| 33 | 255 | Sumer | 50 | F | 9 | 22.3 | 200.7 | 7 | 23.8 | 166.6 | 31.7 | 33.3 | 32.2 | 32.6 | 27.1 |

| | | | | | | | | | | | | | | | |
|---|---|---|---|---|---|---|---|---|---|---|---|---|---|---|---|
| 34 | 60415 | Reeta | 46 | F | 17.4 | 31.1 | 541.14 | 14.3 | 29 | 414.7 | 33.7 | 34.2 | 31.1 | 33.5 | 27.8 |
| 35 | 1485 | Munni | 52 | F | 9.8 | 28 | 274.4 | 19.2 | 22.7 | 435.84 | 38.1 | 35.3 | 32.9 | 30.4 | 21.6 |
| 36 | 2210 | Nageshwar | 50 | M | 12.5 | 25.2 | 315 | 12.6 | 32.2 | 405.72 | 30.6 | 32.9 | 30.4 | 30.4 | 28.6 |
| 37 | 57890 | Ranvijay | 48 | M | 15.4 | 30.4 | 468.16 | 23.9 | 30.6 | 731.34 | 32.7 | 31.7 | 31.7 | 32.6 | 24.5 |
| 38 | 19785 | Surendra | 48 | M | 19.1 | 28.1 | 536.71 | 15.2 | 27.5 | 418 | 32 | 32.7 | 34.5 | 31.7 | 25.1 |
| 39 | 10355 | Bhagwati | 55 | M | 12.6 | 20.1 | 253.26 | 16.4 | 18.3 | 136.12 | 30.2 | 35.9 | 30.6 | 33.3 | 27.5 |
| 40 | 2195 | Anshu | 17 | F | 14.8 | 13.2 | 195.36 | 17.1 | 14.5 | 247.95 | 37.5 | 31.1 | 31 | 32.6 | 19 |
| 41 | 62750 | Shraddha | 18 | F | 12.3 | 19 | 233.7 | 19 | 13.2 | 250.8 | 34.8 | 32.4 | 36.1 | 33.2 | 22.2 |
| 42 | 16945 | Arti | 21 | F | 20 | 29.3 | 586 | 16.3 | 29.1 | 474.33 | 29.1 | 33.2 | 31.9 | 34.3 | 23 |
| 43 | 11063 | Zara | 24 | F | 8.1 | 7.7 | 62.37 | 9.9 | 13.3 | 131.67 | 35.8 | 37.9 | 30 | 32.9 | 22.5 |
| 44 | 57765 | Abdullah | 15 | M | 10.4 | 21 | 218.4 | 9 | 16.2 | 145.8 | 36.6 | 31.7 | 31.7 | 32.4 | 24.9 |
| 45 | 25775 | Mohd Zawed | 20 | M | 8.1 | 19.1 | 154.71 | 19 | 28.8 | 547.2 | 39.7 | 33.3 | 40.1 | 33.5 | 25.8 |
| 46 | 45270 | Aman Kashyap | 24 | M | 11 | 22 | 232 | 10 | 17.4 | 174 | 32.9 | 33.6 | 30 | 33.3 | 27.1 |
| 47 | 43225 | Ramkesh | 21 | M | 19 | 39.4 | 748.6 | 22.1 | 39.7 | 877.37 | 32.9 | 31.7 | 34.8 | 32.6 | 23.8 |
| 48 | 20/21 | Deepika | 23 | F | 10.2 | 15.2 | 155.04 | 8.4 | 17.4 | 146.16 | 25.2 | 33.9 | 27.8 | 32.7 | 22.7 |
| 49 | 540 | Rupsee | 21 | F | 17.9 | 21.6 | 386.64 | 18.7 | 18.5 | 345.95 | 31.7 | 32 | 29.1 | 33.6 | 26.8 |
| 50 | 78370 | Noor | 30 | F | 7.1 | 7.8 | 55.38 | 7.1 | 12.6 | 89.46 | 32.6 | 34 | 30 | 34 | 22.9 |
| 51 | 17364 | Sarla | 27 | F | 10.3 | 13.3 | 136.99 | 12.6 | 11.2 | 141.12 | 28.5 | 31.9 | 29.1 | 32.2 | 20.1 |
| 52 | 91/21 | Rahul | 23 | M | 9.7 | 17.8 | 172.66 | 9.7 | 20.4 | 197.88 | 29.4 | 30.7 | 31.7 | 33 | 36.2 |
| 53 | 17442 | Jai Prakash | 28 | M | 8.4 | 16.5 | 138.6 | 11 | 29.5 | 324.5 | 33.3 | 33.9 | 33 | 34.6 | 22.7 |
| 54 | 1440 | Satendra | 26 | M | 12.1 | 23.9 | 289.19 | 8.4 | 17.4 | 146.16 | 32.9 | 34.6 | 32.9 | 34.9 | 29.4 |

| | | | | | | | | | | | | | | | |
|---|---|---|---|---|---|---|---|---|---|---|---|---|---|---|---|
| 55 | 1685 | Mahendra | 34 | M | 6.4 | 24.9 | 188.16 | 10 | 29.5 | 295 | 33.5 | 34.5 | 29.7 | 33.5 | 26.2 |
| 56 | 17325 | Pooja | 31 | F | 18.1 | 29.4 | 532.14 | 14.9 | 37.2 | 554.28 | 27.2 | 32.9 | 26.2 | 31.1 | 29.4 |
| 57 | 2911 | Zakirun | 35 | F | 14.6 | 14.1 | 205.86 | 9.4 | 11.2 | 105.28 | 28.2 | 33.6 | 30 | 29.4 | 24.9 |
| 58 | 760 | Ramwati | 36 | F | 9.5 | 27.8 | 264.1 | 21.6 | 25.1 | 542.16 | 35.9 | 35.5 | 36.5 | 34.5 | 25.8 |
| 59 | 4665 | Sunita | 41 | F | 8.8 | 15.8 | 139.04 | 15.2 | 25.9 | 393.68 | 33.6 | 30.4 | 32.6 | 31.9 | 22.7 |
| 60 | 4510 | Sushma | 45 | F | 19.4 | 29.3 | 568.42 | 14.3 | 30.6 | 437.58 | 35.2 | 31.7 | 30.7 | 35.2 | 24.5 |
| 61 | 55395 | Anuj | 31 | M | 10.4 | 26.1 | 271.44 | 11 | 30.6 | 336.6 | 34.6 | 32.4 | 33.33 | 34.4 | 22.5 |
| 62 | 2914 | Shubham | 33 | M | 12.6 | 16.5 | 207.9 | 8.3 | 16.1 | 133.63 | 31.3 | 33.3 | 33.2 | 30.7 | 22.3 |
| 63 | 25960 | Md SHARIF | 40 | M | 7.7 | 12.6 | 97.02 | 20.3 | 9.3 | 188.79 | 34.8 | 32.9 | 32.4 | 34.2 | 22.9 |
| 64 | 4865 | Vishwajeet | 36 | M | 19.7 | 28 | 551.6 | 21.6 | 23.8 | 514.08 | 36.6 | 34 | 36.2 | 37.7 | 24.2 |
| 65 | 38109 | Rinzing | 37 | F | 7.4 | 9.4 | 69.56 | 8.7 | 9.1 | 79.17 | 35.2 | 33 | 36.5 | 35.2 | 29.1 |
| 66 | 71430 | Suman | 36 | F | 7.1 | 10.8 | 76.68 | 6.5 | 10.6 | 68.9 | 27.7 | 31 | 29.7 | 29.4 | 26.1 |
| 67 | 3210 | Heval Kumari | 45 | F | 12.7 | 15 | 190.5 | 13.2 | 16.5 | 217.8 | 25.8 | 30.4 | 23.5 | 30 | 16.8 |
| 68 | 57850 | Bindu | 50 | F | 13.9 | 28.5 | 396.15 | 20.7 | 28.4 | 587.88 | 33.9 | 32 | 34.6 | 31.1 | 29.3 |
| 69 | 2235 | Hari Om | 42 | M | 13 | 31.7 | 412.1 | 19 | 32.9 | 625.1 | 36.8 | 37.5 | 38.8 | 37.5 | 22.9 |
| 70 | 924 | Rakesh | 42 | M | 14.3 | 31.9 | 456.17 | 17.8 | 32.7 | 582.06 | 36.9 | 36.2 | 36.2 | 33.6 | 28.3 |
| 71 | 4680 | Ram Prasad | 47 | M | 10.3 | 23.6 | 243.08 | 8.8 | 24.5 | 215.6 | 31.3 | 33.5 | 34 | 33.9 | 25.5 |
| 72 | 4670 | Nirmala | 47 | F | 8.4 | 24.3 | 204.12 | 10.6 | 20.7 | 219.42 | 32.2 | 32 | 30.4 | 29.7 | 27.5 |
| 73 | 2215 | Sumaiya | 49 | F | 9.1 | 19.6 | 178.36 | 13.2 | 23.3 | 307.56 | 38.7 | 32.4 | 36.2 | 34.6 | 25.6 |
| 74 | 4885 | Gunjan | 55 | F | 10.3 | 15.2 | 156.56 | 9.7 | 16.1 | 156.17 | 28.7 | 31.4 | 26.2 | 31 | 28.2 |
| 75 | 2640 | Rajpati | 52 | F | 9 | 8.8 | 79.2 | 8.9 | 11.9 | 105.91 | 27.5 | 32 | 24 | 28.8 | 26.8 |

| | | | | | | | | | | | | | | | |
|---|---|---|---|---|---|---|---|---|---|---|---|---|---|---|---|
| 76 | 17790 | Ram Prasad | 46 | M | 21 | 38.8 | 814.8 | 26.2 | 31.9 | 825.78 | 36.9 | 33.9 | 36.4 | 38.7 | 25.2 |
| 77 | 1825 | Md Iqbal | 53 | M | 7.7 | 11.9 | 91.63 | 15.2 | 14.4 | 218.88 | 31 | 31.7 | 32.9 | 36.2 | 24.5 |
| 78 | 4175 | Shiv Prasad | 53 | M | 7.8 | 6.8 | 53.04 | 7.7 | 10.6 | 81.62 | 35.9 | 38.8 | 39 | 37.5 | 28.2 |
| 79 | 3829 | Dinesh | 52 | M | 15 | 33.5 | 502.5 | 18.5 | 40.7 | 752.95 | 33.8 | 35.9 | 32.6 | 35.7 | 28.9 |
| 80 | 57890 | Ranvijay | 48 | M | 15.4 | 30.4 | 468.16 | 23.9 | 30.6 | 731.34 | 32.7 | 31.7 | 31.7 | 32.6 | 20 |
| 81 | 100 | Vijaybhan | 48 | M | 10.3 | 20.7 | 213.21 | 12.9 | 21.4 | 276.06 | 37.7 | 39 | 34.3 | 31.9 | 27.5 |
| 82 | 5930 | Sushma | 48 | F | 10.4 | 25.5 | 265.2 | 9.4 | 25.2 | 236.88 | 32.7 | 33.6 | 30.7 | 34.6 | 29.1 |
| 83 | 675 | Kali | 55 | F | 15.5 | 30.6 | 474.3 | 16.8 | 28.8 | 483.84 | 26.9 | 32.9 | 27.8 | 32.2 | 26.2 |
| 84 | 1510 | Urmila | 53 | F | 12.6 | 18.5 | 233.1 | 16.8 | 16.7 | 280.56 | 30 | 30.7 | 33.5 | 32 | 27.8 |
| 85 | 5959 | Veena | 54 | F | 14.5 | 19.6 | 284.2 | 12 | 28.2 | 338.4 | 31.6 | 31.3 | 30.7 | 36.2 | 28.6 |
| 86 | 35470 | Aneesh | 18 | M | 7.8 | 17.2 | 134.16 | 10.3 | 29.8 | 306.94 | 29.8 | 30 | 32.3 | 30.4 | 22.9 |
| 87 | 63986 | Azad | 19 | M | 9 | 23.2 | 208.8 | 10.4 | 30.4 | 316.16 | 30.6 | 32.2 | 28.8 | 33 | 21.6 |
| 88 | 580 | Rajdeep | 15 | M | 15.2 | 21.4 | 325.28 | 18.1 | 32.6 | 590.06 | 32.7 | 30 | 32.2 | 32 | 24.2 |
| 89 | 375 | Anilesh | 21 | M | 8.4 | 16.5 | 138.6 | 9.4 | 18.7 | 175.78 | 32 | 28.7 | 33.3 | 29.3 | 28.5 |
| 90 | 44129 | Krisnhna | 22 | M | 11.2 | 26.2 | 293.44 | 16.1 | 26.2 | 421.82 | 36.1 | 33.3 | 31.1 | 31.7 | 22.7 |
| 91 | 65805 | Rahul | 21 | M | 11 | 15.9 | 174.9 | 12.3 | 15.2 | 186.96 | 32.9 | 36.6 | 33.3 | 34.8 | 24.5 |
| 92 | 16845 | Manish | 30 | M | 33.5 | 15.9 | 532.65 | 38.5 | 16.8 | 646.8 | 31.7 | 35.5 | 31 | 33.3 | 22 |
| 93 | 76200 | Satish | 30 | M | 7 | 15.2 | 106.4 | 13.9 | 20.7 | 287.73 | 35.5 | 33.7 | 26.9 | 33.3 | 23.9 |
| 94 | 795 | Laxmi | 37 | F | 9 | 13.6 | 122.4 | 7.2 | 12.3 | 88.56 | 24.9 | 34.2 | 28.2 | 33.6 | 23 |
| 95 | 1690 | Sheela | 35 | F | 14.1 | 16.1 | 227.01 | 16.5 | 25.5 | 420.75 | 34.8 | 33.5 | 30.3 | 33 | 25.2 |
| 96 | 23860 | Kiran | 42 | F | 13.9 | 25.2 | 350.28 | 12.3 | 25.8 | 317.34 | 28.2 | 30.7 | 31.7 | 32.8 | 24.2 |

| | | | | | | | | | | | | | | | |
|---|---|---|---|---|---|---|---|---|---|---|---|---|---|---|---|
| 97 | 3350 | Vidhya | 42 | F | 9.7 | 18.1 | 175.57 | 15.8 | 31.3 | 494.54 | 29.1 | 31.7 | 26.9 | 29.3 | 28.5 |
| 98 | 5920 | Rachna | 46 | F | 7.1 | 10.1 | 71.71 | 8.4 | 13.6 | 114.24 | 35.2 | 34.8 | 32.9 | 36.4 | 20.7 |
| 99 | 39830 | Anup | 15 | M | 11.6 | 18.5 | 214.6 | 11.6 | 24.5 | 284.2 | 36.2 | 33.3 | 35.7 | 31.3 | 26.1 |
| 100 | 36145 | Vishal | 15 | M | 15.1 | 16.5 | 249.15 | 10.6 | 17.8 | 188.68 | 24.9 | 32 | 26.1 | 28.5 | 27.5 |
| 101 | 12685 | Lata | 18 | F | 16.8 | 15.5 | 260.4 | 15.9 | 15.5 | 246.25 | 37.5 | 30.4 | 31.7 | 34.5 | 28.7 |
| 102 | 350 | Saumya | 18 | F | 14.3 | 14.8 | 211.64 | 11.3 | 14.3 | 161.59 | 26.2 | 32.4 | 28.7 | 31.7 | 27.1 |
| 103 | 32620 | Rekha | 22 | F | 11.7 | 18.8 | 219.96 | 26.8 | 18 | 482.4 | 30.1 | 39.2 | 37.2 | 35.3 | 26.5 |
| 104 | 17630 | Fatima | 21 | F | 18.4 | 18.7 | 344.08 | 19 | 20.7 | 393.3 | 30.7 | 30 | 30 | 31 | 25.8 |
| 105 | 79375 | Tanjula | 24 | F | 8.1 | 18.1 | 146.61 | 7.7 | 14.5 | 111.65 | 28.7 | 32.9 | 34.2 | 34.2 | 27.1 |
| 106 | 19730 | Manish | 20 | M | 18.1 | 29.1 | 526.71 | 20 | 33.9 | 687 | 35.5 | 38.2 | 36.5 | 37.5 | 27.5 |
| 107 | 1670 | Rahul | 25 | M | 16.8 | 15.4 | 258.72 | 18.7 | 17.4 | 325.38 | 29.7 | 33.5 | 31.3 | 32 | 20 |
| 108 | 24265 | Rajveer | 27 | M | 15.4 | 26.6 | 409.64 | 28.2 | 16.7 | 470.94 | 32.4 | 33.9 | 32.8 | 32.6 | 27.5 |
| 109 | 240 | Umesh | 31 | M | 8.1 | 16.1 | 130.41 | 15.8 | 26.9 | 425.02 | 36.4 | 33.7 | 35.2 | 33 | 25.2 |
| 110 | 24355 | Rajpal | 40 | M | 11 | 17.8 | 195.8 | 22.3 | 11.9 | 265.37 | 32.6 | 32.4 | 30.4 | 33.5 | 26.2 |
| 111 | 2585 | Vipul | 40 | M | 11.9 | 24.9 | 296.31 | 10.3 | 30.4 | 313.12 | 32.9 | 34.6 | 29.8 | 34.2 | 20 |
| 112 | 16995 | Vinay | 24 | M | 9.4 | 22.5 | 211.5 | 5.5 | 23 | 126.5 | 33.3 | 32.4 | 27.1 | 32.6 | 23.8 |
| 113 | 280 | Sanjeev | 26 | M | 10.6 | 18.1 | 191.86 | 6.8 | 24.3 | 165.24 | 37.7 | 38.1 | 32.9 | 35.9 | 26.5 |
| 114 | 4990 | Sarmaan | 27 | M | 16.5 | 21.3 | 351.45 | 13.2 | 32.6 | 430.32 | 34.3 | 33.3 | 36.5 | 36.1 | 25.2 |
| 115 | 1290 | Naimish | 32 | M | 7.1 | 18.7 | 132.77 | 14.1 | 26.9 | 379.29 | 35.5 | 34.2 | 35.2 | 31.7 | 22.9 |
| 116 | 2025 | Harish | 40 | M | 9 | 19.6 | 176.4 | 14.6 | 32.6 | 459.66 | 35.5 | 33 | 32 | 31.3 | 28.5 |
| 117 | 78755 | Archana | 19 | F | 17.8 | 11.9 | 211.82 | 18.1 | 13 | 235.3 | 38.2 | 34.2 | 35.5 | 34 | 23.6 |

| | | | | | | | | | | | | | | | |
|---|---|---|---|---|---|---|---|---|---|---|---|---|---|---|---|
| 118 | 72650 | Nidhi | 19 | F | 16.8 | 12.5 | 210 | 14.3 | 13 | 185.9 | 34.4 | 33.3 | 32.6 | 33.9 | 30 |
| 119 | 57220 | Pushpa | 30 | F | 9.4 | 10 | 94 | 13.6 | 12 | 163.2 | 30.6 | 31.7 | 30.4 | 30.6 | 24.2 |
| 120 | 2665 | Seema | 28 | F | 16.1 | 14.8 | 238.28 | 19.7 | 22.3 | 439.31 | 30.4 | 34.9 | 28.4 | 31.1 | 28.4 |
| 121 | 17385 | Sandhya | 29 | F | 9.7 | 16.5 | 160.05 | 9.7 | 16.2 | 157.14 | 28.7 | 32.9 | 30 | 26.4 | 24.5 |
| 122 | 15 | Sudha | 26 | F | 11.9 | 19.4 | 230.86 | 9 | 19.4 | 174.6 | 28.4 | 30.3 | 27.1 | 29.1 | 24.2 |
| 123 | 1310 | Deshraj | 32 | M | 8.8 | 10 | 88 | 9.7 | 13.9 | 134.83 | 33.9 | 33.7 | 33.6 | 32.6 | 22.9 |
| 124 | 4660 | Ram Kishore | 35 | M | 22 | 15.8 | 347.6 | 13 | 29.3 | 380.9 | 31 | 33.3 | 33.9 | 35.9 | 27.1 |
| 125 | 1085 | Alok | 37 | M | 16.5 | 24.6 | 405.8 | 23.2 | 39 | 904.8 | 32.6 | 34.8 | 28.5 | 34 | 26.5 |
| 126 | 3330 | Anil | 45 | M | 11.7 | 19 | 222.3 | 15.8 | 30.7 | 485.06 | 31.7 | 34.6 | 29.8 | 31 | 19.4 |
| 127 | 36420 | Ashaarm | 42 | M | 19.4 | 23.5 | 455.9 | 13 | 21.3 | 276.9 | 38.8 | 34.9 | 36.1 | 34.2 | 23.4 |
| 128 | 17210 | Poonam | 34 | F | 10 | 24.8 | 248 | 21.6 | 26.4 | 570.24 | 32.3 | 37 | 36.1 | 30 | 22.9 |
| 129 | 1450 | Yaseem | 33 | F | 9.3 | 11 | 102.3 | 7.4 | 14.3 | 105.82 | 27.8 | 35.2 | 32.4 | 30 | 23.3 |
| 130 | 17135 | Archana Verma | 32 | F | 8.4 | 14.8 | 124.32 | 16.2 | 14.3 | 231.66 | 28.7 | 34.2 | 26.8 | 30.4 | 32 |
| 131 | 4985 | Hariram | 45 | M | 9.4 | 12.3 | 115.62 | 8.6 | 16.1 | 138.46 | 32.4 | 31.4 | 27.5 | 33.9 | 24 |
| 132 | 1655 | Ram Milan | 43 | M | 12.6 | 20.3 | 255.78 | 11.7 | 38.4 | 449.28 | 32.7 | 34.2 | 27.8 | 31.1 | 24 |
| 133 | 17795 | Ramesh | 44 | M | 11 | 22.7 | 249.7 | 11 | 19.7 | 216.7 | 34.3 | 35.9 | 32.6 | 34.6 | 23.6 |
| 134 | Aug-21 | Sanju | 26 | F | 10.4 | 18.7 | 194.48 | 12 | 11.3 | 135.6 | 29.3 | 29.1 | 24.5 | 28.5 | 25.8 |
| 135 | 17195 | Shalini | 29 | F | 14.6 | 15.4 | 224.84 | 14.6 | 22.2 | 324.12 | 28.4 | 32.2 | 25.9 | 31.3 | 22.9 |
| 136 | 17320 | Sangam | 31 | F | 17.8 | 13.9 | 245.64 | 18.9 | 11.5 | 217.35 | 27.1 | 30.7 | 27.5 | 31.7 | 24.2 |
| 137 | 16325 | Seema | 32 | F | 10.6 | 13.3 | 140.98 | 10.6 | 13.2 | 139.62 | 31.5 | 36.8 | 31.7 | 35.9 | 26.8 |
| 138 | 4170 | Bhagwati | 48 | M | 9.4 | 24.2 | 227.48 | 15.5 | 26.2 | 406.1 | 37.5 | 35.2 | 39.1 | 33.9 | 26.8 |

| | | | | | | | | | | | | | | | |
|---|---|---|---|---|---|---|---|---|---|---|---|---|---|---|---|
| 139 | 5025 | Sunil | 46 | M | 27.8 | 23 | 639.4 | 24.5 | 30.4 | 744.8 | 32.6 | 35.5 | 30.4 | 35.2 | 22.6 |
| 140 | 1820 | Bholendra | 47 | M | 11 | 23 | 253 | 12.3 | 25.6 | 314.88 | 32.4 | 30 | 31.1 | 32 | 25.2 |
| 141 | 53375 | Malti | 37 | F | 11 | 21.1 | 232.1 | 16.8 | 23.6 | 396.48 | 30 | 30.4 | 28.4 | 32.6 | 25.5 |
| 142 | 4220 | Arti | 36 | F | 17.1 | 26.8 | 458.28 | 12.3 | 23.6 | 292.74 | 33.3 | 38.1 | 35.5 | 33.6 | 26.8 |
| 143 | 2060 | Poonam | 35 | F | 14.3 | 15.2 | 217.36 | 19.2 | 15.9 | 305.28 | 33.2 | 32.6 | 30 | 29.3 | 23.8 |
| 144 | 17215 | Alok | 55 | M | 15.2 | 29 | 440.8 | 18.2 | 23.3 | 424.06 | 34.5 | 34.9 | 37.2 | 35.5 | 24.5 |
| 145 | 4880 | Vijay | 56 | M | 9.7 | 19.1 | 185.27 | 25.9 | 10.6 | 274.54 | 32.9 | 35.3 | 28.4 | 37.1 | 27.5 |
| 146 | 3320 | Parasnath | 55 | M | 9.4 | 9.4 | 88.36 | 10.3 | 6.4 | 65.92 | 35.5 | 36.1 | 31.7 | 34.5 | 25.2 |
| 147 | 3465 | Amar | 53 | M | 9 | 20 | 180 | 10.4 | 20.3 | 211.14 | 37.4 | 33 | 36.5 | 33.3 | 24.5 |
| 148 | 2265 | Sunita | 45 | F | 9 | 12.3 | 110.7 | 5.9 | 16.1 | 64.99 | 28.7 | 32 | 28 | 30.4 | 22 |
| 149 | 4515 | Parwati | 41 | F | 8.6 | 10.3 | 88.58 | 7.8 | 15.2 | 118.56 | 30.7 | 33.9 | 25.8 | 32 | 20.7 |
| 150 | 59250 | Siya | 43 | F | 10.3 | 20.7 | 213.21 | 8.8 | 14.3 | 125.84 | 33.3 | 31.7 | 33.2 | 30.7 | 26.4 |
| 151 | 17035 | Kavita | 50 | F | 16.4 | 17.6 | 288.64 | 16.5 | 22.1 | 364.65 | 30.4 | 36.1 | 35.5 | 30.8 | 27.5 |
| 152 | 3385 | Anita | 49 | F | 11.7 | 17.5 | 204.75 | 19.4 | 25.9 | 502.46 | 34.9 | 34.2 | 32.6 | 32 | 25.8 |
| 153 | 33685 | Sunil | 60 | M | 10.1 | 13.1 | 132.31 | 9.3 | 14.5 | 134.85 | 33.6 | 33.9 | 33.3 | 36.2 | 23.4 |
| 154 | 4880 | Vijay | 62 | M | 9.7 | 11.1 | 107.67 | 15.9 | 10.6 | 168.54 | 32.9 | 35.2 | 28.4 | 37.1 | 23.5 |
| 155 | 7275 | Ramanand | 65 | M | 9 | 13 | 117 | 14.1 | 10.6 | 149.46 | 39.7 | 38.8 | 41 | 35.6 | 24.6 |
| 156 | 7530 | Anusya | 58 | F | 9.6 | 5.2 | 49.92 | 8.8 | 5.9 | 51.92 | 27 | 29.1 | 27.1 | 32.6 | 23.5 |
| 157 | 7639 | Sushma | 65 | F | 10.1 | 11.2 | 113.12 | 12.6 | 13.2 | 166.32 | 32.2 | 31.3 | 39 | 33 | 27.8 |
| 158 | 60140 | A.K.Shukla | 68 | M | 11.8 | 13.7 | 161.66 | 14.5 | 15.5 | 224.75 | 37.5 | 33.9 | 36.6 | 34.2 | 22.4 |
| 159 | 17614 | RS Shahi | 55 | M | 11.6 | 19.9 | 230.94 | 13.9 | 20.7 | 287.73 | 33 | 31.7 | 30.4 | 34.4 | 31 |

| | | | | | | | | | | | | | | | |
|---|---|---|---|---|---|---|---|---|---|---|---|---|---|---|---|
| 160 | 250 | Radhe Shyam | 52 | M | 14.6 | 21.4 | 312.44 | 15 | 22.8 | 342 | 32.6 | 36.2 | 35.2 | 36.8 | 23.6 |
| 161 | 20356 | K. Srivastava | 57 | M | 10.9 | 13.6 | 148.24 | 9.5 | 14.8 | 140.6 | 35.3 | 35.6 | 33.2 | 33.5 | 25.6 |
| 162 | 25731 | Pradeep | 53 | M | 13.2 | 21.5 | 283.3 | 16.5 | 23.4 | 386.1 | 33.8 | 35.6 | 32.6 | 35.7 | 27.5 |
| 163 | 11775 | Sipahi Singh | 60 | M | 11.7 | 15.6 | 182.52 | 9.5 | 14.6 | 138.7 | 35.6 | 33.9 | 34.7 | 35.6 | 24.6 |
| 164 | 13425 | Sudhir | 56 | M | 9.7 | 19.1 | 185.27 | 20.9 | 10.6 | 221.54 | 32.6 | 33.2 | 27.8 | 34.1 | 24.5 |
| 165 | 72865 | Angoori | 50 | F | 9.3 | 17.3 | 160.89 | 7 | 18.8 | 131.6 | 31.7 | 33.3 | 32.2 | 32.6 | 27.7 |
| 166 | 57210 | Anshu Mohan | 54 | F | 6.4 | 7.5 | 48 | 10.4 | 15.6 | 162.24 | 26.2 | 29.1 | 23.3 | 25.8 | 22.2 |
| 167 | 52895 | Azra | 53 | F | 9 | 8.8 | 79.2 | 8.8 | 11.9 | 104.72 | 27.5 | 32 | 24 | 28.8 | 25.2 |
| 168 | 5915 | Gunjan | 57 | F | 7.1 | 11.9 | 84.49 | 6.8 | 14.6 | 99.28 | 29.4 | 33.5 | 33.9 | 34.2 | 26.8 |
| 169 | 19720 | Narendra | 45 | M | 12.6 | 19.3 | 243.18 | 14.3 | 23.7 | 338.91 | 33.3 | 34.6 | 34.8 | 33.5 | 22.3 |
| 170 | 3130 | Virendra | 49 | M | 23.6 | 13.2 | 311.52 | 18.4 | 25.5 | 469.2 | 32.9 | 34.5 | 32.4 | 37.2 | 24.3 |
| 171 | 16020 | Imran | 18 | M | 11 | 19.7 | 216.7 | 21.5 | 29.7 | 638.55 | 30 | 33.6 | 27.1 | 29.7 | 25.1 |
| 172 | 22255 | A P Singh | 47 | M | 9.4 | 21.1 | 198.34 | 12.3 | 23.6 | 290.28 | 32.2 | 30.6 | 31.1 | 32 | 26.2 |
| 173 | 52000 | Ganesh | 42 | M | 15.8 | 24.8 | 391.84 | 13 | 27.2 | 353.6 | 38.8 | 34.9 | 36.1 | 34.2 | 26.8 |
| 174 | 19786 | Kailashwati | 53 | F | 11.3 | 15.2 | 171.76 | 9.8 | 16.5 | 161.7 | 30.8 | 28.7 | 31.4 | 26.2 | 27.3 |
| 175 | 53900 | Raj Kishor | 44 | M | 10.4 | 13.3 | 138.32 | 8.6 | 17.6 | 151.36 | 32.4 | 30.4 | 28.6 | 33.8 | 24.5 |
| 176 | 37280 | Shambu | 56 | M | 10.8 | 14.6 | 157.68 | 9.8 | 15.4 | 150.92 | 34.6 | 36.7 | 24.5 | 27.6 | 24.3 |
| 177 | 7520 | Sangeeta Pandey | 56 | F | 11.4 | 16.5 | 188.1 | 13.3 | 19.8 | 263.34 | 26.9 | 32.5 | 27.9 | 32.2 | 23.4 |
| 178 | 3590 | Saba Shaheen | 59 | F | 9.8 | 5.4 | 52.92 | 8.9 | 6.2 | 55.18 | 27 | 29.1 | 27.5 | 33.2 | 25.7 |

| | | | | | | | | | | | | | | | |
|---|---|---|---|---|---|---|---|---|---|---|---|---|---|---|---|
| 179 | 59210 | Munni Devi | 52 | F | 8.3 | 13.6 | 112.88 | 12.9 | 14.2 | 183.18 | 29.7 | 32.4 | 26.5 | 31 | 23.2 |
| 180 | 13510 | Radhika | 57 | F | 10.8 | 8.7 | 93.96 | 11.9 | 9.8 | 116.62 | 30.5 | 32.5 | 27.5 | 28.9 | 22.7 |
| 181 | 135 | Gyanti Devi | 56 | F | 11.3 | 8.6 | 97.18 | 13.7 | 10.7 | 146.59 | 31.6 | 33.4 | 28.7 | 26.7 | 22.8 |
| 182 | 60095 | Godavari | 54 | F | 10.5 | 8.3 | 87.15 | 12.3 | 10.9 | 134.07 | 30.2 | 33.6 | 30.7 | 31.2 | 23.6 |
| 183 | 3540 | Mohd Saheyaar | 57 | M | 9.7 | 19.4 | 188.18 | 20.5 | 10.7 | 219.35 | 33.7 | 36.7 | 29.6 | 37.4 | 28.6 |
| 184 | 10710 | Kashiram | 58 | M | 10.9 | 20.6 | 224.54 | 15.7 | 11.5 | 180.55 | 34.5 | 35.6 | 30.7 | 32.6 | 25.6 |
| 185 | 14602 | Sunita | 54 | F | 15.5 | 20.5 | 317.75 | 17.5 | 23.5 | 411.25 | 33.3 | 33.7 | 35.7 | 34.4 | 20.7 |
| 186 | 9255 | Bittan Ji | 59 | F | 10.7 | 6.9 | 73.83 | 13.7 | 15.7 | 215.09 | 26.8 | 29.6 | 27.6 | 28.7 | 27.3 |
| 187 | 1890 | Sheetla Devi | 57 | F | 9 | 13.3 | 119.7 | 11.6 | 15.6 | 180.96 | 28.6 | 30 | 31.2 | 32.6 | 27.9 |
| 188 | 17375 | Gopal | 58 | M | 11.6 | 15.6 | 180.96 | 14.3 | 17.5 | 250.25 | 33.3 | 31.6 | 29.7 | 30.7 | 22.4 |
| 189 | 4505 | Sunita Tiwari | 50 | F | 10.5 | 17.6 | 184.8 | 11.3 | 19.8 | 223.74 | 29.8 | 30.6 | 28.7 | 35.5 | 23.8 |
| 190 | 17725 | Sanjay Singh | 58 | M | 10.6 | 15.6 | 165.36 | 17.8 | 19.7 | 350.66 | 32.4 | 30.5 | 29.8 | 26.7 | 25.4 |
| 191 | 535 | Ram Vilas | 50 | M | 15.6 | 20.5 | 319.8 | 14.4 | 23.6 | 339.84 | 35.5 | 34.6 | 31.7 | 35.4 | 24.5 |
| 192 | 5925 | Rajwati | 60 | F | 9.6 | 13.5 | 129.6 | 11.8 | 14.5 | 171.1 | 34.7 | 32.3 | 33.6 | 34.3 | 25 |
| 193 | 2735 | Kalpati | 60 | F | 8.7 | 10.9 | 94.83 | 9.6 | 12.3 | 118.08 | 30.9 | 32.4 | 33.4 | 35 | 27.7 |
| 194 | 1425 | Ravindra Sharma | 51 | M | 12 | 9.8 | 117.6 | 13.6 | 10.7 | 145.52 | 30.2 | 31.4 | 32.5 | 34.8 | 22.5 |
| 195 | 5955 | Gunjan Sharma | 45 | F | 9 | 12.3 | 110.7 | 8.6 | 16.1 | 138.46 | 28.7 | 32 | 28.3 | 30.5 | 25.5 |
| 196 | 5980 | Veena Verma | 54 | F | 10.3 | 15.3 | 157.59 | 9.9 | 16.7 | 165.33 | 23.4 | 27.5 | 29.8 | 31.5 | 24.3 |
| 197 | 4820 | Rajpati | 58 | F | 9.8 | 5.6 | 54.88 | 8.7 | 6.5 | 56.55 | 27.5 | 29.7 | 27.4 | 32.6 | 25.8 |

| | | | | | | | | | | | | | | | |
|---|---|---|---|---|---|---|---|---|---|---|---|---|---|---|---|
| 198 | 4885 | Munni Devi | 60 | F | 9.5 | 5.9 | 56.05 | 11.2 | 14.7 | 164.64 | 29.9 | 31.2 | 28.7 | 33.7 | 24.5 |
| 199 | 17720 | Parmila | 45 | F | 10.5 | 12.7 | 133.35 | 10.8 | 17.6 | 190.08 | 28.6 | 31.2 | 28.1 | 30.4 | 25.2 |
| 200 | 565 | Geeta Chaurasia | 49 | F | 9.4 | 15.5 | 145.7 | 13.2 | 17.6 | 232.32 | 28.9 | 32.4 | 32.2 | 36.6 | 23.5 |

# ANNEXURE 7

## STATISTICAL ANALYSIS

**Formula**

- **Arithmetic Mean**

The most widely used measure of central tendency is arithmetic mean, usually referred to simply as the mean, calculated as

$$\bar{X} = \frac{\sum_{i=1}^{n} X_i}{n}$$

- **Standard deviation and standard error**

The standard deviation (SD) is the positive square root of the variance, and calculated as

$$SD = \sqrt{\frac{\sum X_i^2 - \frac{(\sum X_i)^2}{n}}{n-1}}$$

where, n= no. of observations. The and SE (standard error of the mean) is calculated as

$$SE = \frac{SD}{\sqrt{n}}$$

- **Minimum and Maximum**

Minimum and maximum are the minimum and maximum values respectively in the measure data and range may be dented as below

Range = Min to Max

and also evaluated by subtracting minimum value from maximum value as below

Range = Maximum value-Minimum value

- **Median**

The median is generally defined as the middle measurement in an ordered set of data. That is, there are just as many observations larger than the median as there are smaller. The median (M) of a sample of data may be found by third arranging the measurements in order of magnitude (preferably ascending). For even and odd number of measurements, the median is evaluated as

M= [(n+1)/2]$^{th}$ observation- odd number

M= [n(n+1)/2]$^{th}$ observation – even number

- **Student's t Test**

Student's t-test was used to calculate the differences between the means of two groups

$$t = \frac{\bar{X}_1 - \bar{X}_2}{SE}$$

where,

$$SE = \sqrt{S^2 \times \left( \frac{1}{n_1} + \frac{1}{n_2} \right)}$$

$S^2$ is the pooled variance and $n_1$ and $n_2$ are number of observations in group 1 and 2 respectively. The degrees of freedom (DF) is calculated as

DF = n1 + n2 – 2

- **Analysis of Variance**

Analysis of variance (ANOVA) is used when we compare more than two groups simultaneously. The purpose of one-way ANOVA is to find out whether data from several groups have a common mean. That is, to determine whether the groups are actually different in the measured characteristic. One way ANOVA is a simple special case of the linear model. For more than two independent groups, simple parametric ANOVA is used when variables under consideration follows Continuous exercise group distribution and groups variances are homogeneous otherwise non parametric alternative Kruskal-Wallis (H) ANOVA by ranks is used. The one way ANOVA form of the model is

$$Y_{ij} = \alpha_{.j} + \varepsilon_{ij}$$

where;

- $Y_{ij}$ is a matrix of observations in which each column represents a different group.
- $\alpha_{.j}$ is a matrix whose columns are the group means (the "dot j" notation means that α applies to all rows of the $j^{th}$ column i.e. the value $\alpha_{ij}$ is the same for all i).
- $\varepsilon_{ij}$ is a matrix of random disturbances.

The model posits that the columns of Y are a constant plus a random disturbance. We want to know if the constants are all the same.

- **Tukey multiple comparison Test**

After performing ANOVA, Tukey HSD (honestly significant difference) post hoc test is generally used to calculate differences between group means as

$$q = \frac{\bar{X}_1 - \bar{X}_2}{SE}$$

$$SE = \sqrt{\frac{S^2}{2}\left(\frac{1}{n_1} + \frac{1}{n_2}\right)}$$

$S^2$ is the error mean square from the analysis of variance and $n_1$ and $n_2$ are number of data in Group 1 and 2 respectively.

- **Simple Linear Correlation**

The relative association between two variables (X and Y) was calculated according to Karl Pearson correlation coefficient (r) method. The correlation coefficient also called as "simple correlation coefficient" is calculated as

$$r = \frac{\Sigma xy}{\sqrt{(\Sigma x^2 \Sigma y^2)}}$$

or,

$$r = \frac{\Sigma XY - \dfrac{\Sigma X \ \Sigma Y}{n}}{\sqrt{\left( \Sigma X^2 - \dfrac{(\Sigma X)^2}{n} \right) \left( \Sigma Y^2 - \dfrac{(\Sigma Y)^2}{n} \right)}}$$

The value of r should be either positive, zero or negative; should be ranged from -1 to +1 and has no units of measurement. A positive correlation implies that for an increase in the value of one of the variables, the other variable also increases in value; a negative correlation indicates that an increase in value of one of the variables is accompanied by a decrease in value of the other variable and zero correlation indicates that there is no linear association between the magnitudes of the two variables; that is, a change in magnitude of one does not imply a change in magnitude of the other.

- **Statistical significance**

Level of significance "*P*" is the probability signifies level of significance. The mentioned P in the text indicates the following:

$P > 0.05$ - not significant (ns)

$P < 0.05$ - just significant (*)

$P < 0.01$ - moderate significant (**)

$P < 0.001$ - highly significant (***)

URKUND

# Urkund Analysis Result

**Analysed Document:** thesis final (1).docx (D110143081)
**Submitted:** 7/5/2021 9:38:00 AM
**Submitted By:** neeta4lko@bbdu.ac.in
**Significance:** 10 %

## Sources included in the report:

SEX DETERMINATION USING MAXILLARY SINUS AND RAMUS OF MANDIBLE - A RETROSPECTIVE STUDY BASED ON C.pdf (D46342774)
Dissertation OMR.docx (D34126895)
Sowmya Final Thesis.pdf (D34364165)
unund plagarism final copy.docx (D46271779)
FULL DISSERTATION WITHOUT REFERENCES for print.docx (D85873016)
afaq thesis.docx (D62769392)
a0310aee-7096-48f5-a043-c0d08b2d3245
https://scielo.conicyt.cl/pdf/ijmorphol/v26n4/art03.pdf
https://www.researchgate.net/publication/285045801_The_frontal_sinus_morphology_in_radiographs_of_Brazilian_subjects_Its_forensic_importance
https://www.ncbi.nlm.nih.gov/pmc/articles/PMC6477950/
https://www.joooo.org/journal-article-file/1684
https://www.researchgate.net/publication/327554991_Evaluation_of_gender_based_on_the_size_of_maxillary_sinus_and_frontal_sinus_using_paranasal_sinus_view_radiographs_in_Maharashtra_population_India
https://healthdocbox.com/Headaches_and_Migraines/92080282-Conventional-frontal-sinus-imaging-a-tool-in-gender-determination-original-study.html
https://www.researchgate.net/publication/313385249_Use_of_Frontal_Sinus_and_Nasal_Septum_Pattern_as_an_Aid_in_Personal_Identification_and_Determination_of_Gender_A_Radiographic_Study
https://www.researchgate.net/publication/260105208_Forensic_importance_of_maxillary_sinus_in_gender_determination_A_morphometric_analysis_from_Western_Uttar_Pradesh_India
https://www.researchgate.net/publication/307951622_Normative_Morphometry_of_Adult_Sudanese_Mandible_A_3D_Computerized_Tomography_Based_Study
https://www.ncbi.nlm.nih.gov/pmc/articles/PMC3970383/
https://www.jpma.org.pk/article-details/9753
https://www.ipinnovative.com/journals/IJMI/article-download/full-text//11216
https://www.ncbi.nlm.nih.gov/pmc/articles/PMC4799523/